

# What does pulmonary–renal syndrome stand for?

Taghreed S. Farag<sup>a</sup>, Abeer S. Farag<sup>b</sup>

Pulmonary–renal disorder (PRS) is an emergency situation described by a rapidly progressive course without an early intervention. It is appropriate time to review this disorder, this is may be attributable to frequent patients' attendance to pulmonologist with both vague pulmonary and/or renal symptoms with disproportionate lack of information concerning consequent care. In addition, the outcome data for PRS still confined to little studies with limited follow-up. An updated working knowledge of PRS including the disease pathogenesis, complications as well as quickly advancing field focused on current new immunomodulatory therapies which offer life-saving options for refractory disease. An often-multi-disciplinary team is required for management. Early rapid identification relies upon a high index of clinical suspicious, careful medical evaluation, accessible laboratory investigations, imaging study, histopathology, with exclusion of differential diagnosis. An accurate diagnosis, exclusion of

## Introduction

Pulmonary–renal syndrome (PRS) is an emergency situation described by a rapidly progressive course without an early intervention. It is an appropriate time to review this disorder; this may be attributable to frequent attendance of patients to the pulmonologist with both vague pulmonary and/or renal symptoms with disproportionate lack of information of consequent care. In addition, the outcome data for PRS are still confined to a few studies with limited follow-up. An updated working knowledge of PRS will be useful including the disease pathogenesis, complications as well as quickly advancing field focused on current new immunomodulatory therapies that offer life-saving options for refractory disease.

An often-multidisciplinary team is required for management. Early rapid identification relies on a high index of clinical suspicious, careful medical evaluation, accessible laboratory investigations, imaging study, and histopathology, with exclusion of a differential diagnosis.

An accurate diagnosis, exclusion of infection, close monitoring of the patient as well as timely initiation of aggressive therapy are crucial for the patient's outcome. The mortality rate of PRS reaches up to 25–50% [1].

## Pulmonary–renal syndrome

PRS are defined as clinical syndromes characterized by diffuse alveolar hemorrhage (DAH) combined with rapid progressive glomerulonephritis (RPGN) [2–4].

infection, close monitoring of the patient as well as timely initiation of aggressive therapy are crucial for the patient's outcome. The mortality rate of PRS, reach up to 25–50 % [1].

*Egypt J Bronchol* 2018 12:1–13

© 2018 Egyptian Journal of Bronchology

*Egyptian Journal of Bronchology* 2018 12:1–13

**Keywords:** diffuse alveolar hemorrhage, glomerular filtration rate, pulmonary–renal syndromes, rapid progressive glomerulonephritis:

Departments of, <sup>a</sup>Chest Diseases, <sup>b</sup>Pathology, Faculty of Medicine for Girls, Al-Azhar University, Cairo, Egypt

Correspondance to Taghreed S. Farag, MD, Chest Diseases Department, Faculty of Medicine for Girls, Al-Azhar University, Al-Zahraa University Hospital, 02-26854947– 11517 Al-Abbassia, Cairo, Egypt; e-mail: drtaghreedsaied@gmail.com

**Received** 18 January 2017 **Accepted** 14 May 2017

The DAH is characterized by hemoptysis, low hematocrit with bilateral diffuse alveolar infiltrate, and hypoxemic respiratory failure [5]. However, RPGN is a kidney disorder described on a clinical basis by a rapid decrease in glomerular filtration rate of no less than 50% within a brief period of time, which varies from days up to 3 months [6].

## Causes and differential diagnosis of the pulmonary–renal syndrome

There is a broad list of etiologies that can cause this syndrome (Table 1). Systemic small-vessel vasculitis is the main underlying causal factor of PRS, mainly small renal as well as pulmonary vessels vasculitis. PRS can be classified according to the following [2–7]:

- (1) Morphological criteria (size of the affected vessels, presence or absence of granulomas).
- (2) Etiological criteria (idiopathic or secondary forms).
- (3) Immunological criteria [anti-neutrophilic-cytoplasmic antibodies (ANCA)-associated vasculitis, immune-complex vasculitis, or caused by antibasement antibodies).

## Pathogenesis of pulmonary–renal syndrome

A variety of mechanisms are implicated in the pathogenesis of PRS syndrome:

---

This is an open access article distributed under the terms of the Creative Commons Attribution-NonCommercial-ShareAlike 3.0 License, which allows others to remix, tweak, and build upon the work noncommercially, as long as the author is credited and the new creations are licensed under the identical terms.

- (1) ANCA-mediated injury.
- (2) Injury induced by anti-glomerular basement membrane (anti-GBM) antibodies.
- (3) Immune-complex-mediated vasculitis of small vessels.
- (4) Drug-induced vasculitides.

Multiple centers have proposed that the development of PRS in 60–70% of patients is related to autoantibodies to ANCAs; however, 20% is related to anti-GBM antibodies [7–10].

(1) ANCA are antibody groups that interact with cytoplasmic antigens in human neutrophils. Despite a large variety of ANCA directed against abundant neutrophilic components, only two forms of ANCA [proteinase 3 (Pr3) and myeloperoxidase (MPO)] are considered to be interrelated to small-vessel vasculitis [3]. Pr3 and MPO are detected in the azurophilic granule of neutrophils and can be expressed on the cell surface in stimulated polymorphonuclear leukocyte cells. MPO are considered the target antigens for perinuclear anti-neutrophilic-cytoplasmic antibodies (P-ANCA) however, Pr3 are the target antigens for cytoplasmic ANCA (C-ANCA). Binding of ANCA with Pr3 on the endothelial surface induces the release of lytic enzymes, interleukin-8 chemoattractant, and reactive oxygen species. Neutrophils subsequently aggregate on the endothelium, causing inflammation and damage to the vasculature; finally, cell necrosis and apoptosis and occur that contribute toward the vascular inflammatory process [4,11–14]. Identification of ANCA could be both by indirect immunofluorescence (IF) and by enzyme-linked immunosorbent assay (ELISA) [4,8]. By an indirect IF test on ethanol-fixed neutrophils for ANCA, three types of antibodies can be observed on the basis of their cellular staining pattern: a perinuclear pattern, a diffuse cytoplasmic granular pattern, and an atypical pattern [4,10,11].

- (a) PRS in ANCA-positive systemic vasculitis: ANCA antibodies are identified in nearly 60–70% of patients presenting with PRS [7–10]. ANCA do not prove a definite etiology, but enable a differential diagnosis of three main systemic vasculitides syndromes: Wegener's disease or Wegener's granulomatosis (WG), microscopic polyangiitis (MPA), and Churg–Strauss syndrome (CSS) (Tables 1 and 2) [4].
- (b) Recently, there have been attempts to change the eponym of WG to ANCA-associated granulomatous vasculitis, which describes the pathology and the disease process [15].

**Table 1 Pulmonary–renal syndromes: clinical entities classified according to the pathogenesis [4,7,10,11]**

**1: ANCA associated systemic vasculitis, make up 60% of all PRS\*\***

**ANCA positive vasculitis**

- Wegener's granulomatosis (WG): C-ANCA or Anti-PR3
- Churg–Strauss syndrome (CSS): P-ANCA or Anti-MPO
- Microscopic polyangiitis (MPA): P-ANCA or Anti MPO
- Drug-associated ANCA-positive vasculitis (Propylthiouracil, D-Penicillamine, Hydralazine, Allopurinol, Sulfasalazine)

**2: Non-ANCA associated systemic vasculitis**

**a) ANCA-negative systemic vasculitis**

- Behçet's disease
- Henoch–Schönlein purpura
- Cryoglobulinemic vasculitis
- IgA nephropathy

**b) Anti-GBM antibodies, make up 20% of all PRS**

- Goodpasture's syndrome

**c) Autoimmune connective tissue disease**

- Autoimmune rheumatic diseases (immune complexes and/or ANCA mediated)
- Systemic lupus erythematosus (SLE) (Immune-complex mediated vasculitis)
- Scleroderma
- Rheumatoid arthritis
- Mixed collagen vascular disease (systemic sclerosis, polymyositis)

**d) Thrombotic microangiopathy**

- Antiphospholipid syndrome
- Thrombotic thrombocytopenic purpura
- Infectious diseases
- Neoplasm
- DAH complicating idiopathic pauci-immune glomerulo-nephritis

**e) Miscellaneous**

- Paraneoplastic Vasculitis
- Inflammatory Bowel Disease

CSS: Churg–Strauss syndrome; C-ANCA: cytoplasmic anti-neutrophilic-cytoplasmic antibodies; DAH: diffuse alveolar hemorrhage; p-ANCA, perinuclear anti-neutrophilic-cytoplasmic antibodies; MPA: Microscopic polyangiitis; SLE: Systemic lupus erythematosus; WG, Wegener's granulomatosis. \*\*They receive similar treatments – but the prognosis is worse if anti-Pr3 is present.

The triad of systemic necrotizing vasculitis describes WG, that is, necrotizing granulomatous inflammation of the upper and/or the lower respiratory tract, focal necrotizing vasculitis of medium and small arteries, including venules and arterioles, and necrotizing immune glomerulonephritis [16]. The incidence of the disease has been predicted to be up to 8.5/million (range: 5.2–12.9/million), with a male-to-female ratio of 1 : 1. The disease frequently affects whites (80–97%), with a mean age at the time of presentations of 40–55 years, although it can occur at any age [17]. The lungs are affected in 90% of cases. In a small percentage of patients, a limited WG that spares the kidney and with no evidence of systemic vasculitis has been reported [17,18]. C-ANCA is found in more than 85% of

**Table 2 Clinical presentations, laboratory investigations, and histopathological features of some causal factors of pulmonary-renal syndromes [4,7]**

	ANCA- associated vasculitis			Non-ANCA associated systemic vasculitis	
	WG	MPA	CSS	GP	SLE
Clinical presentation	Conduction deafness with Eustachian tube damage, collapse of nasal bridge cartilage, orbital scleritis, proptosis	GN reported in 90%, Pulmonary in 50%, DAH in 33% of cases, Pleurisy & pl. effusion. Asthma, fibrosis, Hemoptysis & occasionally pulmonary edema. The upper airway is much less prominently affected by MPA. Other organs affection: [MSK 60%, Skin - 40%, CNS 30%, GiT 50%].	Late onset asthma, Sinusitis, rhinitis. Eosinophilia > 10%, GIT disturbance with mesenteric eosinophilic infiltration, Myositis, (Cardiac failure) mono or polyneuropathy, migratory pulmonary opacities on PCX-R.	50% present with RPGN, 50% present with PRS	Photosensitivity , Malar rash, Discoid rash, polyserositis, Oral ulcers, non-erosive arthritis polyserositis (pleural, pericardial)
General symptoms of vasculitis	+	+	+	-	+
Granuloma formation	+	-	+	-	-
Possibility of PRS	+	+	++	+	++
Laboratory investigations					
ANCA	80–90%	80–90%	50–70%	Absent	Absent
Pr3-antibody	~70%	~30%	~10%	<30%	Absent
MPO-antibody	~20%	~60%	~60%	Absent	Absent
Blood Eosinophilia	Absent	Absent	Common	Absent	Absent
Anti-GBM-Ab	Absent	Absent	Absent	95%	Absent
Anti-ds-DNA, ↓C3 and C4	Absent	Absent	Absent	Absent	Positive
Prominent BAL findings	Neutrophilia, RBCs and siderophages (>30%) if DAH	RBCs and siderophages (>30%) if DAH	Eosinophilia		
Renal biopsy					
Light microscopy	Necrotizing granulomatous vasculitis, capillaritis	Necrotising vasculitis with few or no immune deposits on immunofluorescence (pauci-immune)	Eosinophil-rich granulomatous infiltration. Vasculitis histologically indistinguishable from WG and MPA.	Segmental to global fibrinoid necrosis with crescent formation in 90% progressing to fibrous crescents	Lupus nephritis
Immuno-histopathology	Pauci-immune GN without immune-complex deposits			<b>Linear</b> IgG deposits in the GBM	<b>Granular</b> deposits of IgG, IgM, IgA & complement

ANCA, antineutrophil cytoplasmic antibodies; CSS, Churg–Strauss syndrome; DAH, diffuse alveolar hemorrhage; GBM, glomerular basement membrane; GP, Goodpasture’s syndrome; IC, immune complex; MPA, microscopic polyangiitis; MPO, myeloperoxidase; Pr3, proteinase 3; PRS, pulmonary–renal syndrome; RPGN, rapid progressive glomerulonephritis; SLE, systemic lupus erythematosus; WG, Wegener’s granulomatosis; MSK, musculoskeletal; ~, nearly , +, common; ++, more common; -, uncommon or absent.

patients with generalized WG and in 60% of patients with the limited form of the disease. P-ANCA is nonspecific, frequently observed in other vasculitic syndromes or isolated necrotizing glomerulonephritis [3].

- (c) MPA is a systemic small-vessel vasculitis that is confined to the microvessels and is always associated with a focal segmental necrotizing glomerulonephritis (80–100% of patients), pulmonary capillaritis (10–30%), skin lesions, and arthralgias [19]. It is differentiated from WG by the absence of upper airway

involvement; also, ~40–80% of patients with MPA have P-ANCA directed against neutrophil myeloperoxidase (MPO-ANCA). Positive P-ANCA/MPO-ANCA and a negative serological test for hepatitis B are, in general, suggestive of MPA [3]. Unlike ANCA-associated granulomatous vasculitis, the level of MPO-ANCA titers is not associated with disease activity [17].

- (d) CSS is a rare systemic and pulmonary vasculitis, with an incidence of fewer than three cases/million. A higher incidence was

estimated in asthmatic patients (64 cases/million), with a male-to-female ratio of 2 : 1. CSS typically presents with an initial asthma/sinusitis phase, followed by a marked blood and tissue eosinophilia; the final stage is a vasculitic phase, which can progress to severe respiratory and renal failure [19]. Roughly 35–70% of patients with CSS have positive P-ANCA/MPO-ANCA, whereas only 10% have positive Pr3 ANCA [3]. Renal disorders are milder in CSS compared with WG, MPA, and Goodpasture's syndrome [20].

(e) PRS in ANCA-negative systemic vasculitis: PRS in ANCA-negative systemic vasculitis is extremely uncommon [3] and has been described only infrequently in Behçet's disease, in Henoch–Schönlein purpura, in immunoglobulin (Ig) A nephropathy, and in mixed cryoglobulinemia (Table 1) [4]. In Henoch–Schönlein purpura, acute capillaritis and DAH involve the deposition of IgA immunocomplexes along the pulmonary alveoli [3].

(f) ANCA-positive PRS without systemic vasculitis: idiopathic PRS:

This group includes patients presenting with DAH, RPGN, and positive ANCA (either Pr3 or MPO), but without other manifestations of systemic vasculitis. Fever, malaise, weight loss, generalized body ache, and arthralgias may coexist. Mortality during the first episode of the syndrome exceeds 50%. It is not clear whether the syndrome represents either a limited type of MPA or a variant of Wegener's syndrome [3].

(2) PRS associated with anti-GBM antibodies:

Goodpasture's syndrome:

Goodpasture's syndrome is extremely rare (one case/million). The disease principally influences Whites of any age, with a slight male predominance. Despite its rarity, this syndrome is accountable in nearly 20% of acute renal failure cases because of RPGN [21]. Genetic and environmental factors have been implicated in the pathogenesis of Goodpasture's syndrome. The disease has been found in brothers and in identical twins. 80% and more of patients carry the HLA alleles DR15 or DR4, whereas the alleles DR7 and DR1 are rarely established, signifying that the latter may play a defensive role [22]. As the majority of patients present infrequently, there may be an etiology other than genetic predilection. Environmental factors for example

smoking-related lung injury, infections or inhalation injuries, such as cocaine inhalation, or past hydrocarbon exposure are triggering factors for pulmonary capillaritis causing DAH or 'full-blown' Goodpasture's syndrome [4].

In Goodpasture's disease the production of antibodies occurs against an intrinsic antigen to the GBM (etiology unknown). Antibodies may precede clinical signs by weeks or months. Anti-GBM antibodies, mainly to IgG1 or IgG3, interact with small numbers of epitopes ( $E_A$  and  $E_B$ ) on the noncollagenous domain of the  $\alpha 3$  chain of type IV collagen, a particle released in the BM of renal tubule, renal glomeruli, alveoli, retinal capillaries, and chorioid plexus [16,17]. Renal injury in RPGN occurs mainly because of binding of anti-GBM antibodies to GBM, which trigger complement and protease activations, causing damage of the capillaries, basal membranes, impairment of the Bowman's capsule filtration barrier, with flooding of RBCs, followed by an invasion of fibrinogen and macrophages, inducing proteinuria and crescent development [3,4].

Anti-GBM antibodies recognized utilizing different immunoassays have a sensitivity of 95–100% and a specificity of 90–100% for Goodpasture's syndrome. In patients with negative anti-GBM antibodies, a lung or a renal biopsy with IF showing linear antibody deposition within the alveolar or the GBM establishes the diagnosis. However, in up to 10% of patients with Goodpasture syndrome, DAH is present without renal affections and is similar to isolated pulmonary capillaritis. Lung biopsies with IF studies can differentiate both [15].

(3) Immune-complex-mediated disease: systemic lupus erythmatoses (SLE) is the most widely recognized underlying factor of PRS mediated by immune-complex. This is an autoimmune disease that involves pathological autoantibody production to double-stranded DNA throughout reactions involving T helper cells as well as B cells [23]. DNA–anti-DNA immune complexes are released within the glomeruli and trigger glomerular complement, causing the release of chemoattractants together with inflammatory cytokines. A continual inflammatory process results in extracellular matrix deposition within the renal mesangium [24]. Immune-complex-mediated vasculitis results in an isolated necrotic pulmonary capillaritis with extravasations of damaged erythrocyte directly into alveolar



spaces, causing alveolar hemorrhage [23]. Essential mixed cryoglobulinemia (type II) is another uncommon reason for PRS caused by immune-complex deposition. It is considered to be initiated in the majority of cases by chronic infectivity by hepatitis C virus [24].

- (4) Drug-induced vasculitides are generally initiated by tiny particles forming immune-complex deposition within the pulmonary and renal capillaries. They are frequently ANCA positive (prevalently MPO). Some drugs may possibly consider as haptens denote that they can cause immune reactions just while coupled to a carrier protein. Propylthiouracil and hydralazine are frequent causal drug induced vasculitides [3,25], and commonly showing dosage dependent hazard [3,26].

#### **Pathology and pathophysiology of pulmonary–renal syndrome**

Small-vessel vasculitis, necrotic pulmonary capillaritis, as well as focal proliferative glomerulo-nephritis are the characteristic pathological features of PRS [27].

Among the histopathologies of DAH (pulmonary capillaritis, pulmonary hemorrhage, diffuse alveolar damage, and various histologies), pulmonary capillaritis is the most common. Pulmonary capillaritis differs from pulmonary vasculitis. Pulmonary vasculitis refers to inflammation of lung vessels of any size, whereas pulmonary capillaritis is restricted to the micro-circulation of the lung (destructive inflammation affecting arterioles, venules, and alveolar capillaries). Despite this, both may be encountered in systemic vasculitides and in connective tissue disorders [15,27]. Pulmonary capillaritis has an exclusive histopathologic appearance consisting of an interstitial mainly neutrophilic infiltration, fibrinoid necrosis of the alveolar capillary walls, and leukocytoclasia. The infiltrating neutrophils undergo cytoclasia; nuclear debris accumulates within the interstitium, causing interstitial and alveolar edema with hyaline membrane formation [15]. After recurrent attacks or episodes of DAH, interstitial fibrosis may develop [28]. These injuries disrupt perfusion and increase pulmonary capillary permeability [3], causing flooding of blood into the alveoli, resulting in hypoxemia and hypocapnia with impairment of oxygen transfer [4].

Extensive glomerular crescent formation (crescentic glomerulonephritis) is the fundamental pathologic finding of RPGN that is observed by light microscopy and electron microscopy. The pathological aspect of crescentic glomerulonephritis is a focal rupture of

glomerular capillaries, basement membranes, and blood extravasations, followed by an invasion of macrophages and fibrinogen with the development of extracapillary cellular proliferation (crescents formation). Fibrinoid necrosis is commonly encountered, in addition to microvascular thrombi [29].

There are numerous pathological varieties relying on the correct etiology. Necrotizing granulomata with WG is infrequently observed on renal biopsy, and direct proof of small-vessel vasculitis is also infrequent [30]. The three major pathologic features on WG lung biopsy include granuloma, inflammation of the vascular wall (arteriolar, venular, or capillary), and areas of geographic necrosis [31]. The histologic criteria of CSS include necrotizing vasculitis, eosinophilic tissue infiltration, and extravascular granulomas [32]. Extensive crescent formations are usually found in glomerular tuft disease. The occurrence of interstitial infiltration, with or without fibrosis or tubular atrophy, has a poor prognosis.

Electron microscopy and IF examinations of pauci-immune glomerulonephritis biopsy sample indicate a lack of immune-complex deposits, as well as complement or Igs. These profiles of necrotizing vasculitis are observed in MPA [4].

In an IF examination, the type and deposition pattern of Igs differ (either linear, capillary, granular, or mesangial, all within the GBM). Only in Goodpasture syndrome can the anti-GBM antibody be detected as linear deposits along the glomerular and/or the alveolar basement membrane. However, the granular pattern deposit of complement and Ig is observed in Lupus and postinfectious glomerulonephritis, and also in necrotizing vasculitis (pauci-immune glomerulonephritis) [3]. Interestingly, in immune-complex vasculitis, an alternate profile may be detected, typically with a granular pattern of IgA, IgM, IgG, or complement [3].

#### **Diagnostic workup of pulmonary–renal syndrome**

- (1) The diagnosis of PRS in the ICU is challenging. There is no single specific test, and the symptoms and signs are usually vague. There is an overlap with other common ICU presentations such as sepsis and cardio-respiratory morbidity.
- (2) The clinical presentation of PRS is variable, and could be related to acute respiratory and/or renal failure, a common symptom of systemic vasculitis, as well as the underlying pathology.

- (3) Acute exacerbation of the underlying pathology or infectious complications secondary to severe immunosuppressive therapy of the underlying cause are the most common triggering factors of PRS [15].

The three basic steps for the diagnosis of PRS as with any systemic vasculitis involve the following:

- (1) Careful clinical evaluation of present and past illnesses.
- (2) Confirmation of the diagnosis by laboratory investigations and examinations of biopsy samples.
- (3) Exclusion of an alternative diagnosis for vasculitis.

#### **Clinical manifestations**

- (1) Breathlessness is a frequent clinical presentation of PRS [4].
- (2) Presentation of patients with DAH can range from fever and cough, often acute or sub acute (<1 week), with or without hemoptysis, to severe respiratory distress [28]. Many patients show rapid deterioration and are admitted to the ICU with an acute respiratory and/or renal failure [4].
- (3) Clinically apparent hemoptysis (absent in 1/3 of patients) may be present; 2/3 have at least mild hemoptysis (<200 ml/24 h). If massive, many of them require intubation [28].
- (4) In patients with hemoptysis, bleeding from the upper respiratory tract and gastrointestinal bleeding sources must be excluded. Alternative diagnoses such as pulmonary embolism, pneumonia, congestive heart failure, severe mitral stenosis, and drug exposure, that is, propylthiouracil and cocaine as possible causes should also be excluded [27].
- (5) Acute onset (days to weeks) of acute renal injury may be suggested by admission because of severe oliguria (400 ml/day), signs of nephritic syndrome, rapid impairment of renal function, presence of proteinuria, and active urinary sediments. These features have diagnostic as well as prognostic value. If there is no early intervention for the patients, progression to end-stage renal failure may occur, necessitating dialysis [31].
- (6) Flu-like illness is an early common symptom of ANCA-related vasculitis and involves fever, generalized body ache, myalgias, malaise, bony ache, and loss of appetite and weight. These are reported in more than 90% of cases and usually occur within days to months of development of vasculitis or nephritis [5]. Migratory polyarthropathy, painful cutaneous nodules or ulcerations, and abdominal pain are the most common complaints following the vasculitis attack [4].

- (7) Otitis media, sinusitis, nasal mucosal ulceration, and subglottic stenosis are the most common presenting clinical manifestations of vasculitis of the upper respiratory tract [32].
- (8) An accurate ophthalmology examination for the suspicion of retinal vasculitis or episcleritis, and a dermatological examination for leukocytoclastic vasculitis and the nasopharynx for saddle nose deformities or nasal septal erosion should be considered [32].

#### **Laboratory studies**

All available specimens, that is, sputum, blood cultures, and serological investigations have to be obtained to exclude bacterial or viral infectivity [33].

- (1) Arterial blood gases for the assessment of oxygenation and acid base status.
- (2) Complete blood pictures with differential leukocyte count: results may probably be normal, and anemia may be present in patients with renal failure or a bleeding source elsewhere. Evidence of hemolysis with damaged erythrocytes on the blood film may possibly reveal causal factors, that is, thrombotic thrombocytopenic purpura, Thrombocytopenia reported secondary to cytotoxic drugs, anti-phospholipid syndrome, or SLE [15]. Eosinophilia of 13% or more is indicative of CSS [4].
- (3) Increased erythrocyte sedimentation rate and C-reactive protein may occur in active vasculitis, but may be nonspecific [4].
- (4) Serum electrolytes, that is, liver function tests, renal function tests, lactate dehydrogenase, and creatine phosphokinase). Serum creatinine can be normal at presentation, but may be abnormally elevated with disease progression. Abnormally elevated tissue enzyme (i.e. lactate dehydrogenase, creatine phosphokinase) levels may suggest significant inflammation causing myalgias [6].
- (5) Abnormal prothrombin time, partial thromboplastin time, and international normalized ratio are reported in SLE, coagulation disorders, and drugs [15].
- (6) Serological markers for the underlying cause:
  - (a) Determination of serum antibodies, that is, anti-GBM and/or ANCA is the most important step [34].
  - (b) SLE should be considered with high titers of antinuclear antibody.
  - (c) ANCA by ELISA subtyping: ANCA-positive is observed in 90% of patients with WG and the majority of them have C-ANCA with Pr3 specificity, particularly when the lung is affected [17,18]. Also, ANCA-positive was reported in 80% of patients with MPA, and

most of them reveal p-ANCA with MPO specificity [19]. On the other hand, ANCA type and specificity is not specific for these disorders, as few cases of WG are p-ANCA-positive, as well as c-ANCA-positive were observed in few patients with MPA [33–36]. According to the International Consensus Statement on Testing and Reporting of ANCA, combining indirect IF essays and ELISAs for Pr3 and MPO is more accurate than the use of either assay alone [18]. It is important to note, however, that not all patients with ANCA-associated vasculitis will test positive for ANCA, and therefore, ANCA are not considered a diagnostic criterion [3]. However, ANCA have also been observed in numerous other autoimmune nonvasculitic disorders, that is, inflammatory bowel disease, rheumatoid arthritis, and autoimmune hepatitis as well as in infectious and neoplastic diseases [10].

- (d) Cryoglobulin titer results should be negative in patients with ANCA-related diseases as symptoms of cryoglobulinemia are similar to those in ANCA-related disease [33–36].
  - (e) Hepatitis markers: hepatitis C is linked to mixed cryoglobulinemia, whereas hepatitis B is linked to polyarteritis nodosa [33].
  - (f) Tests for antiphospholipid antibodies, anti-double strand-DNA, and complement fractions C3 and C4 must be requested if there is any suspicion of SLE or antiphospholipid syndrome [35].
- (7) Urine analysis with microscopic examination: proteinuria is almost constantly present, but is seldom more than 2–3 g/24 h. Also, microscopic hematuria is always detected and might be direct evidence for glomerular membrane damage because of glomerulonephritis. Microscopic hematuria with proteinuria are most commonly detected early in WG and MPA [31]. Nephritic urinary sediments (dysmorphic red blood cell and/or red blood cell casts), if crescents more than 50%, indicate a poor prognosis [31].
- (8) Urine and serum protein electrophoresis: this may be considered a key investigation in patients with RPGN with the aim of confirming or excluding the light-chain disease or overt multiple myeloma as a reason for the presenting symptoms [3,4].

#### Imaging studies

There are benefits of imaging to determine the severity of pneumonic capillaritis causing DAH:

- (1) Plain chest radiography or computed tomography:
  - (a) There are abnormal radiographic pictures even without clinically significant manifestations. Normal chest radiography is recorded in 25% of cases, and in such cases, pulmonary embolic disease should be excluded [4].
  - (b) The most common findings include bilateral diffuse alveolar infiltrates, mainly perihilar infiltrates, toward the lower zones or areas of consolidations with air bronchogram with preserved normal areas; up to diffuse consolidation mimic an adult respiratory distress syndrome picture; rarely DAH radiographic pictures appear as ground glass opacities. These changes are usually nonspecific and often frequently difficult to differentiate from infection or acute pulmonary edema [3,4,32].
  - (c) Vasculitis as a cause of DAH is highly suggested by multiple cavities, diffuse ground glass infiltrations, and nodules. WG is commonly associated with cavitations; diagnostic workup should be performed for exclusion of alternative diagnoses, that is, cavitating pneumonia, mycobacterial, or malignant disease [4].
  - (d) Lymphadenopathy is usually not present in DAH, but usually add suspicious of infectivity or malignancy [5].
  - (e) Radiographic resolution in general takes 3–4 days (or sometimes even 1 day) only if the source of bleeding has stopped. The presence of interstitial opacities might be a result of an underlying cause or may indicate the presence of primary pulmonary hemosiderosis, caused by chronic or repeated episodes of DAH [37,38].
  - (f) The finding of Kerley A, B, or C shadows with diffuse alveolar infiltrate indicates an alternative diagnosis, that is, veno-occlusive disease of the lung, cardiogenic pulmonary edema, or mitral valve stenosis [39].
- (2) Nowadays, nuclear imaging, for example, gallium or tagged red blood cell studies, are rarely performed in the evaluation of DAH. Other nuclear studies, which may reveal breakdown of the microcirculatory integrity and RBCs extravasations out of the vessels, have additionally not been shown to be useful [32].
- (3) Renal ultrasound is definitely performed to exclude obstructive uropathy in any patient with acute renal failure [6] and also to establish the presence of two functioning kidneys before a percutaneous renal biopsy [6].



### Pulmonary function tests in stable patients

- (1) Diffusion lung capacity for carbon monoxide (DLCO) can be measured; this is significant if there is an increase of greater than 30%. Recent alveolar hemorrhage increases DLCO, whereas DAH that occurs more than 2 days before the test is unlikely to cause a significant increase in DLCO. Continuous increase in DLCO may be suggestive of progressive alveolar hemorrhage. DLCO measurement maneuvers require breath-holding on an air, carbon monoxide, and helium mixture for around 10 sec. The major disadvantage of this maneuver is that it is difficult and not practical in patients with marked dyspnea or hemoptysis [4]. In contrast, decreased exhaled nitric oxide of exhaled breath condensate may play a role in the diagnosis of DAH [32].
- (2) Restrictive changes, that is ↓total lung capacity and ↓forced vital capacity (FVC), with a preserved ratio of forced expiratory volume in 1 s ( $FEV_1$ )/FVC, may characterize DAH. Frequent attacks of DAH can cause interstitial fibrosis [32].
- (3) Obstructive changes, that is, ↓ $FEV_1$  and ↓ratio of  $FEV_1$ /FVC are less commonly observed in patients with DAH, but if present, may indicate airflow obstruction. Many authors attributed this possibly to flooding of alveolar spaces by blood, which causes neutrophilic infiltration that sequentially releases proteolytic enzymes and reactive oxygen species, which in turn may result in parenchymal destruction and small airway disease, for example, emphysema and bronchiolitis [32].
  - (a) A mixed pattern of obstructive and restrictive lung disease associated with DAH is suggestive of a differential diagnosis causing airflow obstruction and parenchymal destruction, that is, commonly, sarcoidosis, MPA, or WG, occasionally idiopathic pulmonary hemosiderosis, or, less frequently, pulmonary capillaritis, lymphangiomyomatosis, or histiocytosis X [32].

### Bronchoscopy

Bronchoscopic examination, serves three purposes: visual inspection of airway sources of bleeding, exclusion of infection, and obtain lavage samples for various laboratory investigations that is, bacterial, viral, mycobacterial, and fungal cultures, in addition to pneumocystis stains. Evidence supporting DAH is continual or increase blood quantity on three sequential lavage aliquots from a single affected area; Prussian blue staining for bronchioalveolar lavage shows hemosiderin-laden macrophages (siderophages)

[4]. The diagnostic yield is enhanced if the bronchoscopy is carried out within the first 2 days of manifestations instead of later [3,32].

### Tissue biopsy

The gold standard for the diagnosis of PRS is renal and/or pulmonary biopsy when the lung is involved. Transbronchial biopsy specimens are small and unlikely to help establish a diagnosis. Thoracoscopic lung biopsy or open lung biopsy, although invasive and involving considerable risk, is more definitive [3,32]. In general, lung biopsy should only be used as a last option if the diagnosis cannot be confirmed in a different way [4].

In difficult cases with vague symptoms or once there is a suspicion of systemic vasculitis, collagen vascular disease, or Goodpasture's syndrome, renal biopsy is favored and should be performed as soon as possible. Keeping in mind the end goal of assessment of a renal biopsy, the pathologist should correlate complete clinical and laboratory research facility data with Light microscope and IF, and the electron microscopic examinations should be carried out as soon as appropriate [6,35].

In those patients whom can't tolerate or at high-risk operative interference for lung or renal biopsy [3], biopsies from other organs (i.e. skin, sinuses or nerves) can be replaced. Proper treatment should be initiated rapidly even in the absence of histopathological proof to reduce morbidity and mortality in patients with a high clinical suspicion of ANCA-associated or anti-GBM-associated vasculitis and with a positive ANCA or anti-GBM antibody result, respectively [1,3].

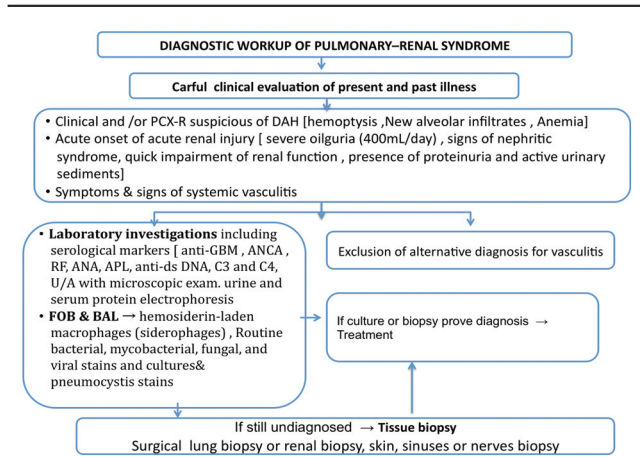
When initial treatment is started, patients should be closely monitored for response to treatment. Radiological clearance, and improvements in arterial blood gases, renal function, neurologic signs, and other signs (such as purpura) can be expected within a few days of initiation of therapy [3] (Fig. 1).

If this diagnostic workup is not conclusive or if is the patient's condition worsens, refractory PRS with a differential diagnosis should be considered, for example, Papiris and colleagues [3,7,40]:

- (1) Drug reactions, sepsis syndrome, or septicemia or exacerbation of the underlying cause.
- (2) Antiphospholipid syndrome with vasculitis



Figure 1



Diagnostic workup of pulmonary-renal syndrome. ANA, anti-nuclear antibody; ANCA, anti-neutrophil cytoplasmic antibodies; anti-ds, anti double strand; APL, anti-phospholipid; BAL, bronchioalveolar lavage; C3 and C4, complement fractions; DAH: diffuse alveolar hemorrhage; FOB, fiberoptic bronchoscopy; GBM, glomerular basement membrane; RF, rheumatic factor; U/A, urinalysis

- (3) Mixed connective tissue diseases, that is, systemic sclerosis, polymyositis.
- (4) Thrombocytopenic purpura.
- (5) Infectious complications of the lung and kidney (e.g. sepsis, tuberculosis, mycoplasma, legionella, cytomegalie-virus, hantavirus, leptospirosis).

Furthermore, a primary renal disorder results in lung disease and resembles the profile of PRS:

- (1) Acute renal failure with pulmonary edema and uremic hemoptysis.
- (2) Thromboembolism in nephrotic syndrome: renal vein thrombosis and/or pulmonary embolism.
- (3) Immunosuppression in renal disease and pneumonia.

In addition, a primary lung disease results in renal disease and resembles the profile of PRS:

- (1) Pulmonary infection with prerenal renal failure and/or postinfectious glomerulonephritis or hematuria in IgA nephropathy.
- (2) Lung cancer with immune-complex nephritis.

#### Treatment of pulmonary-renal syndrome in critically ill patients

- (1) The primary goal of therapy for patients with PRS is to induce remission as fast as possible to minimize irreversible organ damage as well as to prevent further antibody formations. In addition, treatment plans should be focused on causal factors with the prevention of treatment-related toxicity.

- (2) Once the induction-remission phase has occurred, the secondary goal of therapy is to maintain remission with as few side effects as possible.
- (3) Supportive therapies and care should be provided throughout the duration of illness.

Therapy is subdivided into the induction-remission phase and the maintenance phase [41,42].

#### Anti-neutrophilic-cytoplasmic antibodies-associated pulmonary-renal syndrome

##### Induction-remission phase

Immunosuppressive therapy is the basis of treatment of ANCA-associated PRS. Standard remission induction therapy for patients with severe disease generally involves a pulsed intravenous dose of methylprednisolone (500 mg-1 g/day) for 3-5 days; this is coupled with pulsed intravenous cyclophosphamide, which is the preferable drug in severely ill patients with systemic disorders. Intravenous cyclophosphamide is administered every 2-3 weeks at a dose of (15 mg/kg/pulse) on 6-9 occasions or as a daily oral regimen (1-2 mg/kg/day) [3,4,15,43], with a lower dose in those older than 60 years and those with renal impairment. The dose interval and duration of treatment are dependent on the nature of the underlying inflammatory disease and the response [43,44]. Intravenous cyclophosphamide therapy is increasingly favored over oral therapy because of significantly fewer side effects. Optimal dosing with cyclophosphamide is achieved when the lymphocytic count is reduced, but the total white blood count is maintained above 3500. Its undesired effect related to cumulative dose. Hemorrhagic cystitis, bladder cancer, and gonadal toxicity are uncommon but serious side effects of cyclophosphamide therapy [4]. Bone marrow suppression is the most common serious side-effect and regular full blood count monitoring is mandatory [44].

In case of severe renal impairment defined as a serum creatinine (>500 mmol/l) [4] or (serum creatinine > 5.7 mg/dl) [3], plasmapheresis may be beneficial at least for the first week, with the possibility of restoration of renal function [41,42]. Plasmapheresis is a blood-purification procedure used to treat several autoimmune diseases. It is also known as therapeutic plasma exchange (PE). Debates still exist on the beneficial effect of PE in the acute phase. The mechanism of action of PE is largely unknown. PE does not directly influence the ability of the immune system to generate more antibodies, but can be used to dilute and remove antibodies from circulation as well as to eliminate a large fraction of proinflammatory cytokine complement and coagulation factors from the

bloodstream. PE may therefore only offer temporary benefits. It almost certainly decreases progression to end-stage renal disease in those with severe renal failure at attendance [3,4]. There is no established long-standing survival advantage from its application and, in addition, little evidence for its role in the treatment of cases with moderate renal impairment [3].

There are data showing that extracorporeal membrane oxygenation and activated human recombinant factor can be used to treat severe DAH in MPA with unremitting respiratory failure [3]. The mechanism of factor VIIa treatment involves increased thrombin generation on the surface of activated platelets at the sites of hemorrhage [3]. Alternative agents are not commonly used for induction of remission, that is, methotrexate and mycophenolate mofetil (MMF) [Suppressor for B lymphocytes and T cell lymphocytes]. Although methotrexate is contraindicated in severe renal disease, MMF is superior to cyclophosphamide in preservation of normal renal function at 6 months from diagnosis [45]. Treatment with rituximab [Anti-CD20 monoclonal antibody] results in B cells depletion. B cells produce pathogenic autoantibodies and inhibit the cellular interaction, by reduction of both cytokines production and immune complex formations that maintain mononuclear cells and help to sustain the disease [15,46]. A recent trial on rituximab for induction of remission in ANCA-associated disease did not find superior results to the use of standard intravenous cyclophosphamide. With this therapy, nearly 85% of patients achieve remission [[41,42]. Transition to maintenance therapy may occur 6–12 months after the initiation of induction therapy or after clinical remission [47].

#### Maintenance phase therapy

If the patient continues to remain stable or improves, methylprednisolone is switched to prednisone at a dose of 1 mg/kg/day for the first month and tapered over 5–6 months with the aim of complete stoppage. Currently, glucocorticoids are sustained at a low dose for at least 18 months together with steroid-sparing drugs. This is frequently extended to 2 years in total in those with Pr3-positive ANCA with a high incidence of relapse [42]. For maintenance of remission, patients treated with cyclophosphamide have to be switched to either azathioprine or methotrexate. Azathioprine is favored in patients with any degree of renal impairment. The European Practice is to switch from cyclophosphamide to azathioprine within 3- to 6-month intervals from diagnosis. MMF is an alternative for either methotrexate or azathioprine. Remission maintenance therapy is continued for at least 1 year after remission and longer in patients who have suffered relapses. Early stoppage of immune-suppressive therapy is associated with an excessively high relapse rate [4].

#### Treatment of patients refractory to standard therapy

About 10% of patients do not respond adequately to standard therapy and fail to achieve remission. Relapse will occur in 11–57% of patients in remission. Some relapses are severe, resulting in end-organ damage [42]; in such cases, alternative agents have to be used. Recent researches have focused on new biological agents, that is, tumor necrosis factor- $\alpha$  inhibitors (etanercept, infliximab), B-cell depletion agents (MMF), and suppressor of T cells agents (leflunomide and antithymocyte globulin) (Table 3) [48–59]. These new biological agents have been found to be efficient in certain patients, but result in high relapse and complication rates. The majority of data are preliminary and additional investigations are required for accurate conclusions [3,4].

**Table 3 Current biological therapies for the treatment of pulmonary–renal syndrome [48–59]**

Biological therapy	Mood of action	Indication	General comments
Mycophenolate mofetil	Suppressor for both B lymphocytes and T lymphocytes	ANCA-associated vasculitis (remission and maintenance)	Well-tolerated, high relapse rate
Rituximab	Anti-CD20 monoclonal antibody (B-cell depletion)	ANCA-associated vasculitis (remission, refractory to or as a contraindication to treatment)	Effective, preliminary data
Etanercept	Tumor necrosis factor- $\alpha$ inhibitor	WG (maintenance therapy)	Ineffective, higher frequency of infection and malignancies
Infliximab	Tumor necrosis factor- $\alpha$ inhibitor	ANCA-associated vasculitis	Effective, high infection complication rates, high relapse rate
Leflunomide	Suppressor for T cells	WG (remission, maintenance)	Well-tolerated, high relapse rate
Antithymocyte globulin	Suppressor for T cells	Severe refractory WG	Partial or complete remission, high complication rate

ANCA, antineutrophil cytoplasmic antibodies; WG, Wegener's granulomatosis.

### *Supportive therapy*

Careful monitoring of PRS patients is a must because of high rates of fluid and electrolyte imbalance, cardiovascular disorders, neurological and hematological abnormalities, bone marrow suppression, in addition to opportunistic infection [3,60].

Pneumocystis jiroveci pneumonia still carries a mortality of up to 35%. Therefore, prophylactic cotrimoxazole therapy to prevent Pneumocystis jiroveci pneumonia supplemented by folic acid 1 mg/day has been shown to be cost effective in patients with WG; also, it is recommended in patients receiving methotrexate for remission induction or maintenance [44]. Prophylactic antifungal therapy is suggested for patients receiving immunosuppressive drugs during the induction-remission phase. Finally, osteoporosis prophylaxis with calcium and vitamin D supplements and possibly bisphosphonates is advised for every patient treated with glucocorticoids.

Small endotracheal or tracheostomy tubes may be required in patients with WG with the complication of subglottic stenosis resulting in difficult intubation [1,4]. In the management of ARDS, a lung-protective ventilation strategy with small tidal volumes of 6 ml/kg and inspiratory plateau pressures lower than 30 cmH<sub>2</sub>O with permissive hypercapnia may decrease lung injury [1,4]. Inotropic supports are required in hypotensive PRS patients, which may result from dehydration, hemorrhage, and systemic inflammation [4].

The majority of patients develop severe acute renal failure and require hemodialysis in ICU. Irrespective of meticulous treatment, nearly 66% of cases with PRS-related small-vessel vasculitis will require renal transplantation within a maximum of 4 years of attendance [3,60].

### **Goodpasture's syndrome**

Once a diagnosis of Goodpasture's syndrome is suspected, immunosuppressant drugs coupled with urgent daily PE must be immediately initiated. There are data showing that an earlier and aggressive PE decreases plasma anti-GBM antibodies, which may result in a higher likelihood of long-term renal restoration [4,15,46]. Nearly 14 days of complete courses of plasmapheresis are required for the anti-GBM to revert to normal titer [3,46]. If tests for anti-GBM antibodies are found to be negative, plasmapheresis is then discontinued [46].

### **Systemic lupus erythematosus**

DAH secondary to SLE has a poor prognosis, and lupus nephritis requires prompt immunosuppressive therapy with high-dose methylprednisolone and cyclophosphamide to prevent end-stage renal damage [3,15]. To avoid the severe side effects of SLE treatment, that is, bone marrow depression, opportunistic infections, hemorrhagic cystitis, malignant transformations, and premature gonadal failure, current biological therapies such as rituximab and MMF are still being researched. Both drugs result in efficient disease remission in 80% of patients with low toxicity, but with a high relapse rate [3,4,61,62]. New studies have reported that the addition of rituximab to SLE therapies failed to show a significant advantage, although this may be because of poor trial designs [3,4,15].

### **Acute catastrophic antiphospholipid syndrome**

Anticoagulation is the cornerstone of treatment PRS related to acute catastrophic antiphospholipid syndrome [3,63].

### **Thrombotic thrombocytopenic purpura**

In cases of PRS and thrombotic thrombocytopenic purpura, mortality exceeded 90% before the use of PE. Currently, 80% of cases show a good response to treatment with PE. While awaiting PE treatment, plasma transfusions are recommended to make up for the inadequate von Willebrand factor cleavage protein [3,64].

### *Diagnostic barriers*

- (1) Many pulmonologists do not have extensive training or experience in examining the extra-thoracic manifestations of systemic autoimmune diseases, especially in the absence of classic clinical presentations such as the skin exam, joint exam, or neurological exam. In addition, there is no consensus on proper screening laboratory tests.
- (2) The majority of the current trials on biological therapies are preliminary and more researches and investigations are required in the future to ensure avoidance of side effects of systemic steroids as well as to obtain accurate conclusions.

### **Conclusion**

- (1) PRS is an urgent clinical situation which necessitates a high index of suggestion.
- (2) A systematic approach focused on early recognition, confirmation of diagnosis, and



aggressive treatment likely decreases the morbidity and mortality associated with untreated or unrecognized PRS.

- (3) The risks of a PRS and vasculitis have to be kept in mind, particularly in those presenting with bilateral pulmonary infiltration, with one or more of the following: decreased hemoglobin levels, renal failure requiring dialysis, or symptoms and signs suggestive of vasculitis.
- (4) Pneumonia like pictures may be the presenting features, or may be the precipitating factors of PRS. Management of all patients should include empirical broad-spectrum antimicrobial drugs until advanced workup is completed.
- (5) Pulse dose steroids and cyclophosphamide is life threatening drugs for renal and pulmonary involvement.
- (6) Early use of PE, followed by intravenous Ig is life threatening and represents treatment for resistant cases.
- (7) PE has been useful in situations with a concomitant need for anticoagulation.
- (8) Renal transplantation is the only alternative in end-stage renal disease.
- (9) Newer immunomodulatory agents such as those causing tumor necrosis factor blockade, B-cell depletion, and MMF could be used in patients with refractory disease.

#### Financial support and sponsorship

Nil.

#### Conflicts of interest

There are no conflicts of interest.

#### References

- 1 Griffith M, Brett S. The pulmonary physician in critical care illustrative case 3: pulmonary vasculitis. *Thorax* 2003; **58**:543–546.
- 2 Gallagher H, Kwan J, Jayne RW. Pulmonary-renal syndrome: a 4-year, single center experience. *Am J Kidney Dis* 2002; **38**:42–47.
- 3 Papisir SA, Manali ED, Kalomenidis L, Kapotsis GE, Karakatsani A, Roussos C. Bench-to bedside review: pulmonary-renal syndromes – an update for the intensivist. *Critical Care* 2007; **11**:213.
- 4 McCabe C, Jones Q, Nikolopoulou A, Wathen C, Luqmani R. Pulmonary-renal syndromes: an update for respiratory physicians. *Respir Med* 2011; **105**:1413–1421.
- 5 Ioachimescu OC, Stoller JK. Diffuse alveolar hemorrhage: diagnosing it and finding the cause. *Cleve Clin J Med* 2008; **75**:258–280.
- 6 Moroni G, Ponticelli C. Rapidly progressive crescentic glomerulo-nephritis: early treatment is a must. *Autoimmun Rev* 2014; **13**:723–729.
- 7 Kimmel M, Braun N, Alscher MD. Differential diagnosis of the pulmonary-renal syndrome. In: Prabhakar S, editor. *An update on glomerulopathies – clinical and treatment aspects*. InTech; 2011. pp. 291–299.
- 8 Sexena R, Bygren P, Arvastson B, Wieslander J. Circulating autoantibodies as serological markers in the differential diagnosis of pulmonary renal syndrome. *J Internal Med* 1995; **238**:143–152.
- 9 Niles JL, Böttinger EP, Saurina GR, Kelly KJ, Pan G, et al. The syndrome of lung hemorrhage and nephritis is usually an ANCA-associated condition. *Arch Internal Med* 1996; **156**:440–445.
- 10 Falk RJ, Jennette JC. Anti-neutrophil cytoplasmic autoantibodies with specificity for myeloperoxidase in patients with systemic vasculitis and idiopathic necrotizing and crescentic glomerulonephritis. *N Engl J Med* 1988; **318**:1651–1657.
- 11 Bosch X, Guilabert A, Font J. Antineutrophil cytoplasmic antibodies. *Lancet* 2006; **368**:404–418.
- 12 Little MA, Smyth CL, Yadav R, Ambrose L, Cook HT, Sussan Nourshargh S, Pusey CD. Antineutrophil cytoplasm antibodies directed against myeloperoxidase augment leukocyte microvascular interactions in vivo. *Blood* 2005; **106**:2050–2058.
- 13 Xiao H, Heeringa P, Liu Z, Huugen D, Hu P, Maeda D, et al. The role of neutrophils in the induction of glomerulonephritis by anti-myelo-peroxidase antibodies. *Am J Pathol* 2005; **167**:39–45.
- 14 Booth A, Pusey C, Jayne D. Renal vasculitis – an update in 2004. *Nephrol Dial Transplant* 2004; **19**:1964–1968.
- 15 Lara AR, Schwarz MI. Diffuse alveolar hemorrhage. *Chest* 2010; **137**:1164–1171.
- 16 Bacon PA. The spectrum of Wegener's granulomatosis and disease relapse. *N Engl J Med* 2005; **352**:330–332.
- 17 Langford C, Hoffman G. Wegener's granulomatosis. *Thorax* 1999; **54**:629–637.
- 18 Savige J, Davies D, Falk R, Jennette JC, Wiik A. Antineutrophil cytoplasmic antibodies and associated diseases: a review of the clinical and laboratory features. *Kidney Int* 2000; **57**:846–862.
- 19 Schwarz M, Brown K. Small vessel vasculitis of the lung. *Thorax* 2000; **55**:502–510.
- 20 Guillevin L, Cohen P, Gayraud M, Lhote F, Jarrousse B, Casassus P. Churg-Strauss syndrome: clinical study and long-term follow-up of 96 patients. *Medicine* 1999; **78**:26–37.
- 21 Salama AD, Levy J, Lightstone L, Pusey CD. Goodpasture's disease. *Lancet* 2001; **358**:917–920.
- 22 Phelps RG, Jones V, Turner AN, Rees AJ. Properties of HLA class II molecules divergently associated with Goodpasture's disease. *Int Immunol* 2000; **12**:1135–1143.
- 23 Lamprecht P, Holle J, Wolfgang L. Pulmonary haemorrhage in systemic lupus erythematosus. *Lupus* 1997; **6**:445–448.
- 24 Aringer M, Smolen JS. Cytokine expression in lupus kidneys. *Lupus* 2005; **14**:13–18.
- 25 Schwarz MI, Fontenot AP. Drug-induced diffuse alveolar haemorrhage syndromes and vasculitis. *Clin Chest Med* 2004; **25**:133–140.
- 26 Kalra A, Yokogawa N, Raja H, Palaniswamy C, Desai P, Zanotti-Cavazzoni SL, Rajaram SS. Hydralazine-induced pulmonary-renal syndrome: a case report. *Am J Ther* 2012; **19**:e136–e138.
- 27 Collard HR, Schwarz MI. Diffuse alveolar hemorrhage. *Clin Chest Med* 2004; **25**:583–592.
- 28 Costabel U, du Bois RM, Egan JJ, editors. *Diffuse parenchymal lung disease*. Basel, Switzerland: Karger; 2007. pp. 250–263.
- 29 Merkel PA, Choi H, Niles JL. Evaluation and treatment of vasculitis in the critically ill patient. *Crit Care Clin* 2002; **18**:321–344.
- 30 Hudson BG, Tryggvason K, Sundara-moorthy M, Neilson EG. Alport's syndrome, Good-pasture's syndrome, and type IV collagen. *N Engl J Med* 2003; **348**:2543–2556.
- 31 Lau K, Wyatt R. Glomerulonephritis. *Adolesc Med* 2005; **16**:67–85.
- 32 Park MS. Diffuse alveolar hemorrhage. *Tuberc Respir Dis (Seoul)* 2013; **74**:151–162.
- 33 Jennette JC, Wilkman AS, Falk RJ. Diagnostic predictive value of ANCA serology [editorial]. *Kidney Int* 1998; **53**:796–798.
- 34 Mazidi P, Bajestani S, Khan M, Khair T, Luis L. Goodpasture's syndrome: a case report and review of the literature. *Internet J Intern Med* 2008; **7**:1–5.
- 35 Jara LJ, Vera-Lastra O, Calleja MC. Pulmonary-renal vasculitic disorders: differential diagnosis and management. *Curr Rheumatol Rep* 2003; **5**:107–115.
- 36 Davies DJ. Small vessel vasculitis. *Cardiovasc Pathol* 2005; **14**:335–346.
- 37 Papisir SA, Manoussakis MN, Drosos A, Kontogiannis D, Constantopoulos SH, et al. Imaging of thoracic Wegener's granulomatosis: the computed tomographic appearance. *Am J Med* 1992; **93**:529–536.
- 38 Ando Y, Okada F, Matsumoto S, Mori H. Thoracic manifestation of myeloperoxidase-antineutrophil cytoplasmic antibody (MPO-ANCA) related disease. *J Comput Assist Tomogr* 2004; **28**:710–716.
- 39 Jennings C, King T, Tuder R, Cherniack RM, Schwarz MI. Diffuse alveolar hemorrhage with underlying isolated, pauciimmune pulmonary capillaritis. *Am J Respir Crit Care Med* 1997; **155**:1101–1109.



- 40 Brown KK. Pulmonary vasculitis. *Proc Am Thorac Soc* 2006; **3**:48–57.
- 41 Tesar V, Rihova Z, Jancova E, Rysova R, Merta M. European randomized trials: current treatment strategies in ANCA-positive renal vasculitis—lessons from European randomized trials. *Nephrol Dial Transplant* 2003; **18**:v2–v4.
- 42 Hogan S, Falk RJ, Chin H, Cai J, Jennette CE, Jennette JC, Nachman PH. Predictors of relapse and treatment resistance in antineutrophil cytoplasmic antibody-associated small vessel vasculitis. *Ann Intern Med* 2005; **143**:621–631.
- 43 Jones RB, Tervaert JW, Hauser T, Luqmani R, Morgan MD, Peh CA, *et al.*, European Vasculitis Study Group. Rituximab versus cyclophosphamide in ANCA-associated renal vasculitis. *N Engl J Med* 2010; **363**:211–220.
- 44 British Thoracic Society. *Interstitial lung disease guideline; appendix 5, notes on cyclophosphamide therapy in ILD*; British Thoracic Society, September 2008 Thorax 2008; **63**, supplement V. Available at: <http://www.brit-thoracic.org.uk>.
- 45 Hu W, Liu C, Xie H, Chen H, Liu Z, Li L. Mycophenolate mofetil versus cyclophosphamide for inducing remission of ANCA vasculitis with moderate renal involvement. *Nephrol Dial Transplant* 2008; **23**: 1307–1312.
- 46 Levy JB, Turner AN, Rees AJ, Pusey CD. Long term outcome of anti-glomerular basement membrane antibody disease treated with plasma exchange and immunosuppression. *Ann Intern Med* 2001; **134**:1033–1042.
- 47 Jayne D, Rasmussen N, Andrassy K, Bacon P, Tervaert JW, Dadoniene J, *et al.* A randomized trial of maintenance therapy for vasculitis associated with antineutrophil cytoplasmic autoantibodies. *N Engl J Med* 2003; **349**:36–44.
- 48 White ES, Lynch JP. Pharmacological therapy for Wegener's granulomatosis. *Drugs* 2006; **66**:1209–1228.
- 49 Booth A, Harper L, Hammad T, Bacon P, Griffith M, Levy J, *et al.* Prospective study of TNF alpha blockade with infliximab in antineutrophil cytoplasmic antibody-associated systemic vasculitis. *J Am Soc Nephrol* 2004; **15**:717–721.
- 50 Lamprecht P, Voswinkel J, Lilienthal T, Nolle B, Heller M, Gross WL, Gause A. Effectiveness of TNF-alpha blockade with infliximab in refractory Wegener's granulomatosis. *Rheumatology (Oxford)* 2002; **41**:1303–1307.
- 51 Wegener's Granulomatosis Etanercept Trial (WGET) Research Group. Etanercept plus standard therapy for Wegener's granulomatosis. *N Engl J Med* 2005; **352**:351–361.
- 52 Feldman M, Pusey CD. Is there a role for TNF-alpha in antineutrophil cytoplasmic antibody-associated vasculitis? Lessons from other chronic inflammatory diseases. *J Am Soc Nephrol* 2006; **17**:1243–1252.
- 53 Stasi R, Stipa E, Del Poeta GD, Amadori S, Newland AC, Provan D. Long term observation of patients with anti-neutrophil cytoplasmic antibody-associated vasculitis treated with rituximab. *Rheumatology (Oxford)* 2006; **45**:1432–1436.
- 54 Antoniu SA. Rituximab for refractory Wegener's granulomatosis. *Exp Opin Invest Drugs* 2006; **15**:1115–1117.
- 55 Nowack R, Gobel U, Klooker P, Hergesell O, Andrassy K, van der Woude FJ. Mycophenolate mofetil for maintenance therapy of Wegener's granulomatosis and microscopic polyangiitis: a pilot study in 11 patients with renal involvement. *J Am Soc Nephrol* 1999; **10**:1965–1971.
- 56 Langford CA, Talar-Williams C, Sneller MC. Mycophenolate mofetil for remission aintenance in the treatment of Wegener's granulomatosis. *Arthritis Rheum* 2004; **51**:278–283.
- 57 Koukoulaki M, Jayne DR. Mycophenolate mofetil in anti-neutrophil cytoplasm antibodies-associated systemic vasculitis. *Nephron Clin Pract* 2006; **102**:c100–c107.
- 58 Metzler C, Fink C, Lamprecht P, Gross WL, Reinhold-Keller E. Maintenance of remission with leflunomide in Wegener's granulomatosis. *Rheumatology (Oxford)* 2004; **43**:315–320.
- 59 Schmitt WH, Hagen EC, Neumann I, Nowack R, Flores-Suarez LF, van der Woude FJ, European Vasculitis Study Group. Treatment of refractory Wegener's granulomatosis with antithymocyte globulin (ATG): an open study in 15 patients. *Kidney Int* 2004; **65**:1440–1448.
- 60 Candan S, Pirat A, Varol A, Torgay A, Zeyneloglou P, Arslan G. Respiratory problems in renal transplant recipients admitted to intensive care during long-term follow-up. *Transplant Proc* 2006; **38**:1354–1356.
- 61 Appel GB, Contreras G, Dooley MA, Ginzler EM, Isenberg D, Jayne D, *et al.* Aspreva Lupus Management Study Group. Mycophenolate mofetil versus cyclophosphamide for induction treatment of lupus nephritis. *J Am Soc Nephrol* 2009; **20**:1103–1112.
- 62 Smith KG, Jones RB, Burns SM, Jayne DR. Long term comparison of rituximab treatment for refractory systemic lupus erythematosus and vasculitis: remission, relapse, and re-treatment. *Arthritis Rheum* 2006; **54**:2970–2982.
- 63 Hanly JG. Antiphospholipid syndrome: an overview. *CMAJ* 2003; **168**: 1675–1682.
- 64 Fontana S, Kremer Hovinga JA, Lammle B, Mansouri Taleghani B. Treatment of thrombotic thrombocytopenic purpura. *Vox Sang* 2006; **90**:245–254.