

Ultrasonographic evaluation of the diaphragm

Youssriah Y. Sabri^a, Sabah A.M. Hussein^b, Ahmed A.M. Baz^a,
Amal A.M. Aglan^a

Background Ultrasonography is a promising technique for structural and functional evaluation of the diaphragm. It is accurate, reproducible, and portable with no ionizing radiation. Multiple studies have reported ultrasonography as the modality of choice for evaluation of the diaphragm.

Objective The aim was to assess the role of ultrasound (US) in the evaluation of the diaphragm, either normal or abnormal, through evaluating its morphology, integrity, and measuring different parameters such as diaphragmatic thickness, thickening fraction, and excursion with proper assessment of supra/infradiaphragmatic lesions that affect the diaphragm.

Patients and methods In all, 118 patients were recruited from the Chest and Radiology Departments, Cairo University, in the period from January to July 2019. All patients were subjected to history taking, clinical examination, and ultrasonographic assessment of the diaphragm. High-frequency linear transducer of 7.5–12 MHz was used for imaging the diaphragm and measuring its thickness. A low-frequency curvilinear transducer with a frequency of 3.5–5 MHz was used for assessing diaphragmatic excursion.

Results Cases were grouped into two groups, those with normal US findings of the diaphragm represented group A, while patients with any diaphragmatic abnormality represented group B. Group B included 41 patients with

intrinsic (56.09%) and extrinsic diaphragmatic abnormalities (46.34%). Five (12.2%) cases have thickened diaphragm; two (4.9%) cases have thinned-out diaphragm; two (4.9%) cases showed congenital diaphragmatic defects; three (7.3%) cases showed acquired diaphragmatic defects; 10 (24.4%) cases showed diaphragmatic weakness; and nine (21.95%) cases showed diaphragmatic paralysis (7.6%).

Conclusion US is the technique of choice for assessing diaphragmatic movement on suspicion of malfunctioning. Ultrasonography is a promising technique for structural and functional evaluation of the diaphragm.

Egypt J Bronchol 2019 13:690–698

© 2020 Egyptian Journal of Bronchology

Egyptian Journal of Bronchology 2019 13:690–698

Keywords: diaphragm function, diaphragm morphology, ultrasonography

Departments of, ^aRadiology, ^bPulmonology, Faculty of Medicine, Cairo University, Cairo, Egypt

Correspondence to Sabah A.M. Hussein, MD, 10 Gomaa Saleh Street, Helwan, Cairo 1456, Egypt Tel: 01000938175; fax: 0223674707; e-mail: sabah.hussein@kasralainy.edu.eg

Received: 31 August 2019 **Accepted:** 24 November 2019

Published: xx xx 2020

Introduction

The diaphragm is the major respiratory muscle. Dysfunction can be caused by conditions either directly involving the diaphragm, such as trauma, cardiothoracic surgery, or adjacent thoracic (e.g. basal pulmonary atelectasis, pleural effusion, pneumonia, or tumors) and abdominal pathology (e.g. upper abdominal masses, extensive abdominal fluid) [1]. Diaphragm movement can also be affected by central nervous system diseases, phrenic nerve involvement, motor neuron disease and diseases of the neuromuscular junction [2].

Imaging of the diaphragm can be anatomic or functional. Although all radiologic modalities can be used for anatomic imaging, functional imaging is mainly performed with fluoroscopy, ultrasonography, and magnetic resonance (MR) fluoroscopy [3]. Ultrasound (US) is a fast, cheap, easily available, and a bedside technique that provides real-time image and does not involve ionizing radiation [4]. US focuses mainly on the posterior and lateral parts of the diaphragm, which are the muscular crural components innervated by the phrenic nerve, rather than the anterior central tendon seen in fluoroscopy, which moves 40% less with respiration [5].

M-mode US can be used to assess diaphragmatic movement quantitatively by using two parameters: direction of motion and amplitude of excursion. The diaphragmatic movement is considered normal if the diaphragm moves toward the transducer during inspiration, with excursion of greater than 4 mm and difference in excursion between the domes of less than 50% [6]. Two-dimensional B-mode US can be used to measure diaphragm thickness at the zone of apposition during inspiration or expiration using the intercostal approach [3]. Muscle fibers shorten with contraction and cause muscle thickening. Increase in diaphragmatic thickness during inspiration has been used as an indirect measurement of muscle fiber contraction [7].

Ultrasonography is a promising technique for the evaluation of the structure and dynamic function of the diaphragm, being the modality of choice for

This is an open access journal, and articles are distributed under the terms of the Creative Commons Attribution-NonCommercial-ShareAlike 4.0 License, which allows others to remix, tweak, and build upon the work non-commercially, as long as appropriate credit is given and the new creations are licensed under the identical terms.

evaluation of diaphragm paralysis, especially in neonatal, pediatric, and critically ill patients [8].

This work investigated the role of US in the evaluation of the diaphragm, either normal or abnormal, through evaluating the diaphragm morphology, integrity, and measuring different parameters such as diaphragmatic thickness, thickening fraction (TF), and diaphragmatic excursion, associated with proper assessment of supradiaphragmatic or infradiaphragmatic lesions that affect the diaphragm.

Patients and methods

Patients

This cross-sectional study involved 118 patients (236 hemidiaphragms) (62 women, 66 men) with age range from 2 to 83 years (mean age 50.42 years). The cases were recruited from Chest Department Inpatients, Chest Department Outpatient Clinics, Radiology Department, Surgery Outpatient Clinics, and Emergency Unit in Kasr El-Aini Hospitals, Cairo University from January 2019 to July 2019. Causes of referral for sonographic evaluation of the diaphragm included focused assessment of the diaphragm with sonography in trauma, postoperative assessment, elevated diaphragm, acute abdomen, and diaphragmatic assessment during transthoracic US. The Human Study Committee of Kasr El Aini Hospital, Cairo University approved this study. Written informed consent was also obtained from the study patients.

Methods

All patients were subjected to full history taking, detailed clinical examination, and ultrasonographic assessment of the diaphragm together with assessment of supradiaphragmatic and infradiaphragmatic structures. The following probes were used: a high-frequency linear transducer of 7.5–12 MHz for imaging the diaphragm and measuring its thickness; a low-frequency curvilinear transducer (3.5–5 MHz) for assessing the level of diaphragmatic excursion.

Technique

- (1) Patient positioning: examinations were done in the supine position and semisitting position during spontaneous respiration.
- (2) Views: the following views were done to assess the diaphragm (Fig. 1).
 - (a) Intercostal view: this view is obtained by transducer placement on the ninth intercostal space in the anterior axillary line. Diaphragm visualization at the zone of apposition using this approach.

- (b) Anterior subcostal view: transducer is placed between the midclavicular and anterior axillary lines, and directed medially, cranially, and dorsally.

- (c) Posterior subcostal view: similar to the anterior subcostal view, the transducer is placed in the posterior subcostal region (at the mid-scapular line); this view requires patients to be seated (this was not applicable in all cases).

- (d) Subxiphoid view: the transducer is placed below the xiphoid in a transverse orientation, angled upward (cranially) for visualization of both sides simultaneously.

(3) Measurements: the following measurements were obtained for all patients.

- (a) Diaphragm thickness: using the intercostal approach with a high-frequency linear transducer, B-mode applied, thickness is measured at the zone of apposition inferiorly to the costophrenic angle. In case of thickening, Doppler application was done to detect any abnormal vascularity with histopathological correlation for any abnormal diaphragmatic lesions.

- (b) Thickening fraction: calculated throughout the formula [7]:

- (c) Diaphragmatic excursion: using the intercostals/subcostal approach with a low frequency curvilinear transducer, M-mode applied, excursion is obtained in normal/deep breathing and sniff; amplitude can also be measured.

Results

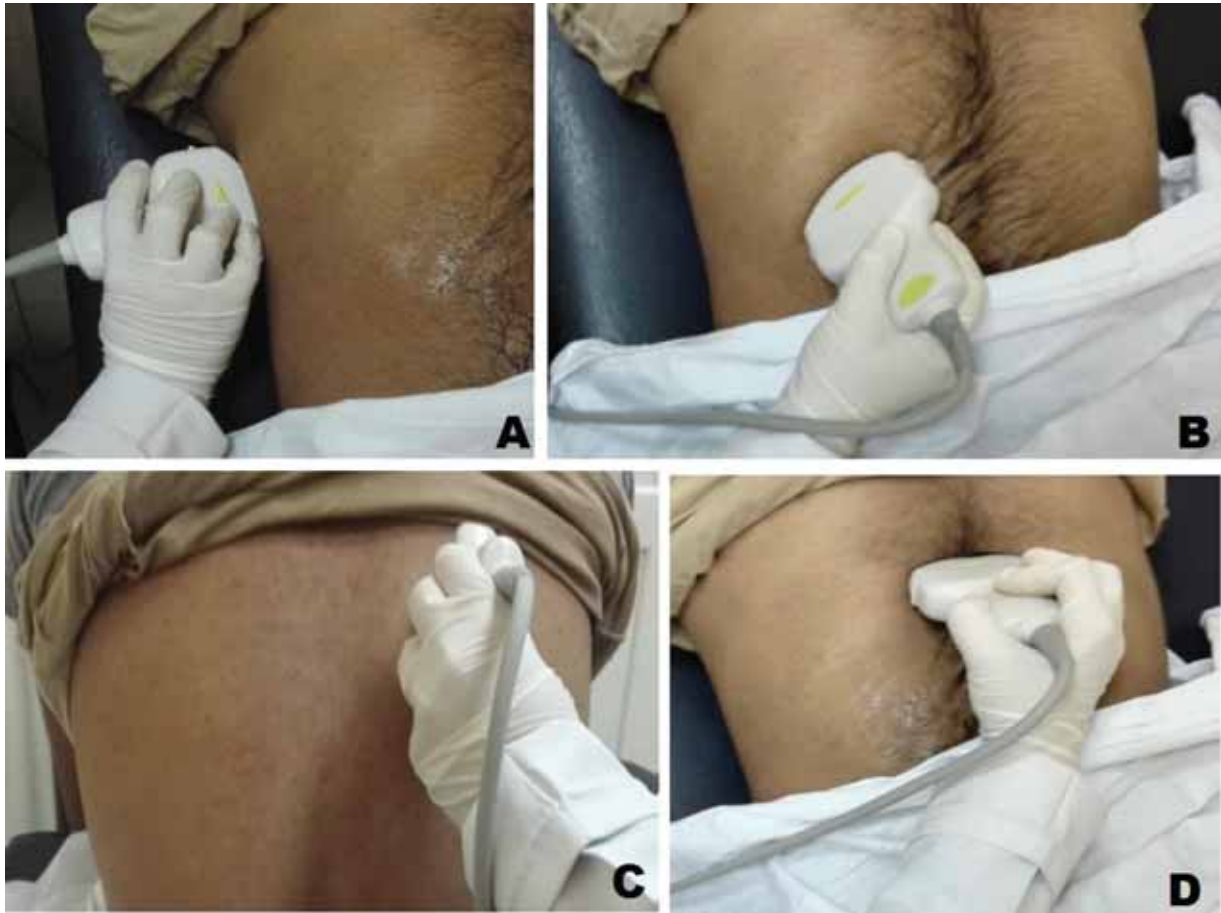This cross-sectional study included 118 patients who were subdivided into two groups, those with normal US findings of the diaphragm represented group A; however, patients who showed any diaphragmatic abnormality is represented by group B.

Group A: 77 (65.25%) patients (Fig. 2), (37 men, 40 women) with age range from 2 to 75 years (mean age was 31 years). In this group, there were normal diaphragm morphology with normal parameters (Fig. 3) with no defect detected or supradiaphragmatic and infradiaphragmatic lesions.

The following parameters were recorded:

- (1) Diaphragmatic thickness: ranges from 1.8 to 3 mm with the mean diaphragmatic thickness being 2.3 mm. Mean thickness of the right

Figure 1



Different views which was used to assess the diaphragm. (a) Probe positioning into the anterior axillary line to obtain the intercostal view at the zone of apposition; (b) curvilinear probe is placed to obtain the anterior subcostal view; (c) patient is sitting to obtain the posterior subcostal view; (d) subxiphoid view for qualitative assessment of both hemidiaphragms.

hemidiaphragm was 2.37 mm while the mean thickness of the left hemidiaphragm was 2.23 mm.

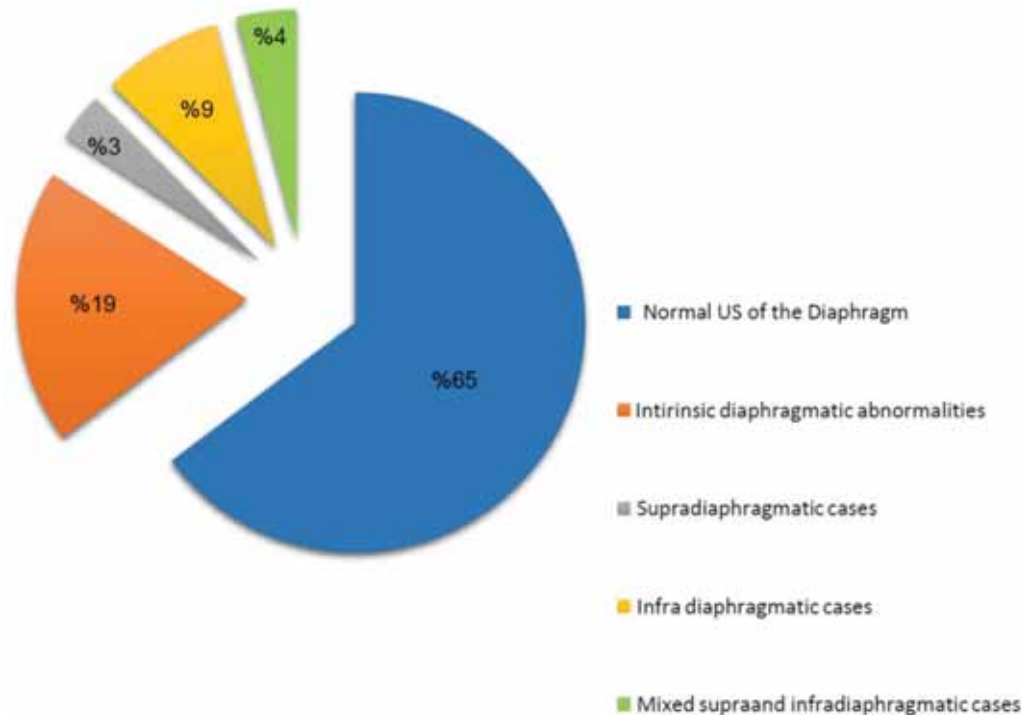
- (2) TF: ranges from 22 to 78%, mean TF was 38.4%. Mean TF of the right hemidiaphragm was 35.4% while the mean TF of the left hemidiaphragm was 41.4%.
- (3) Diaphragmatic excursion:
 - (a) Excursion in normal breathing ranges from 0.9 to 3.6 cm and the mean excursion was 2 cm. Mean excursion for the right hemidiaphragm was 1.85 cm, while the mean excursion for the left hemidiaphragm was 2.31 cm.
 - (b) Excursion in deep breathing ranges from 2 to 11.9 cm and the mean excursion was 5.9 cm. Mean excursion for the right hemidiaphragm was 5.1 cm, while the mean excursion for the left hemidiaphragm was 6.7 cm.
 - (c) Excursion in sniffing ranges from 1.4 to 11.5 cm and the mean excursion was 4.25 cm. Mean excursion for the right

hemidiaphragm was 3.5 cm, while for the left hemidiaphragm was 5 cm.

Group B included 41 (34.75%) patients (six women, 35 men) with age range from 2 to 83 years (mean age was 40.78 years). This group involved patients with intrinsic and extrinsic diaphragmatic abnormalities (Fig. 2).

- (1) Intrinsic diaphragmatic abnormalities (Table 1): 23 (56.09%) patients (five women, 18 men) with age range from 2 to 73 years (mean age was 30.4 years). Abnormalities were detected either in morphological features of the diaphragm (thickness changes/integrity defect) or in diaphragmatic function by dynamic US. Patients with a diaphragm thickness of more than 3 mm were considered to have thickened diaphragm and they were five (12.2%) out of total 41 patients with diaphragmatic abnormality. Doppler examination was done in all five cases where four patients

Figure 2



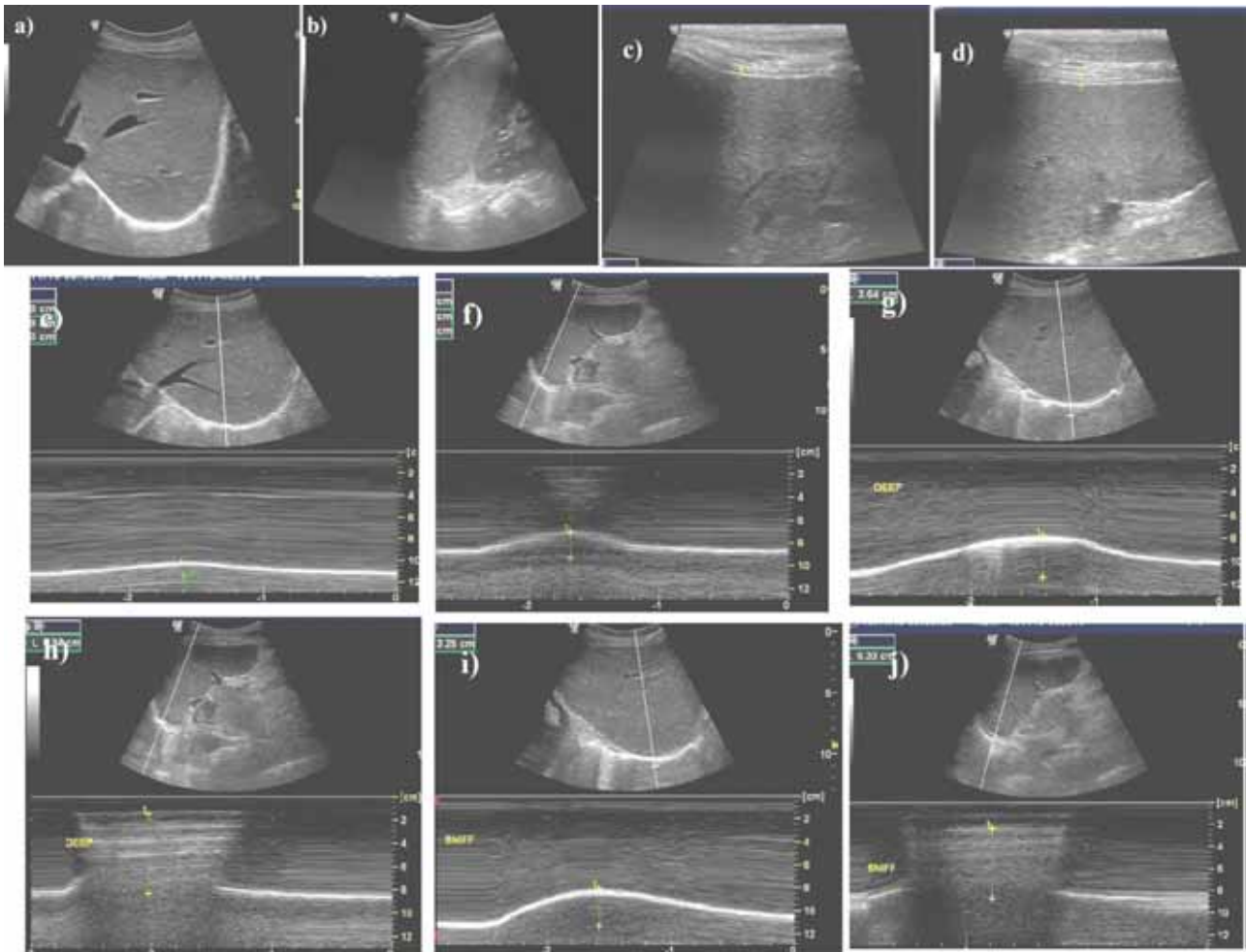
Patients' classification regarding ultrasound findings.

showed abnormally increased internal vascularity; two of them were pathologically proven mesothelioma and the other two cases were metastatic adenocarcinoma. The remaining patient with no abnormally detected vascularity had pleural plaques and history of asbestos exposure. Patients with thinned-out diaphragm (diaphragm thickness <1.8 mm) were two (4.9%), one patient with a hump (Fig. 4) with associated abnormal diaphragmatic movement and one patient postcardiothoracic surgery with associated diaphragmatic paralysis. Patients with congenital diaphragmatic defects were two (4.9%) patients with large defects detected with herniated bowel loops in the chest. Patients with acquired diaphragmatic defect were three (7.3%) patients, one patient with traumatic injury to the diaphragm, one patient with iatrogenic injury (postoperative), and one patient with sliding hiatal hernia. Patients with diaphragmatic weakness (diaphragmatic excursion was lower than normal range, <0.9 in normal breathing, <2 in deep breathing, and <1.4 in sniffing) were 10 (24.4%). They included three patients with associated pleural thickening, three patients presented with elevated diaphragmatic copula, three patients were with postoperative complications, and one patient with stab injury. Patients with diaphragmatic paralysis (absent

diaphragmatic excursion with or without TF of $<22\%$) were nine (21.95%). They included four patients who were referred for postoperative assessment, three patients were traumatic, one patient with elevated copula, and one patient with thickened diaphragm.

- (2) Extrinsic diaphragmatic abnormalities: 19 (46.34%) patients (nine women, 10 men) with an age range from 6 to 83 years (mean age was 53.6 years). Extrinsic abnormalities were either supradiaphragmatic or infradiaphragmatic or both. Supradiaphragmatic lesions were documented in four (9.8%) patients; one patient was with basal pulmonary lesion and associated effusion. Doppler showed increased vascularity of the diaphragm and it was pathologically proven to be spindle cell carcinoma; one patient was with Pott's disease and associated effusion. Two patients were traumatic with associated hemothorax. Infradiaphragmatic lesions were present in 10 (24.4%) patients causing limited diaphragmatic excursion (weakened diaphragm); three patients were with ascites; two patients with subphrenic abscess; three patients with traumatic collection, and two patients with elevated copula. Mixed supra and infra diaphragmatic lesions were present in five (12.2%) patients who all showed abdominal collection and pleural effusion, causing limited diaphragmatic movement.

Figure 3



Normal sonography of the diaphragm. (a) Anterior subcostal view of right hemidiaphragm; (b) intercostal view of left hemidiaphragm showing the normal diaphragm. Intercostal view showing (c) average diaphragmatic thickness (right hemidiaphragm=2.7 mm, (d) left-hemidiaphragm=2.5 mm with adequate thickening fraction (right=45%/left=50%). Normal excursion in normal, deep breathing, and sniff test: (e) right=1.8 cm in normal breathing, (g) 3.4 cm in deep breathing, and (i) 3.2 cm in sniffing, (f) left=2.1 cm in normal breathing, (h) 6.8 cm in deep breathing, and (j) 6.3 cm in sniffing.

Table 1 Sonographic findings in patients with intrinsic diaphragmatic abnormalities (total number of patients with diaphragmatic abnormality=41)

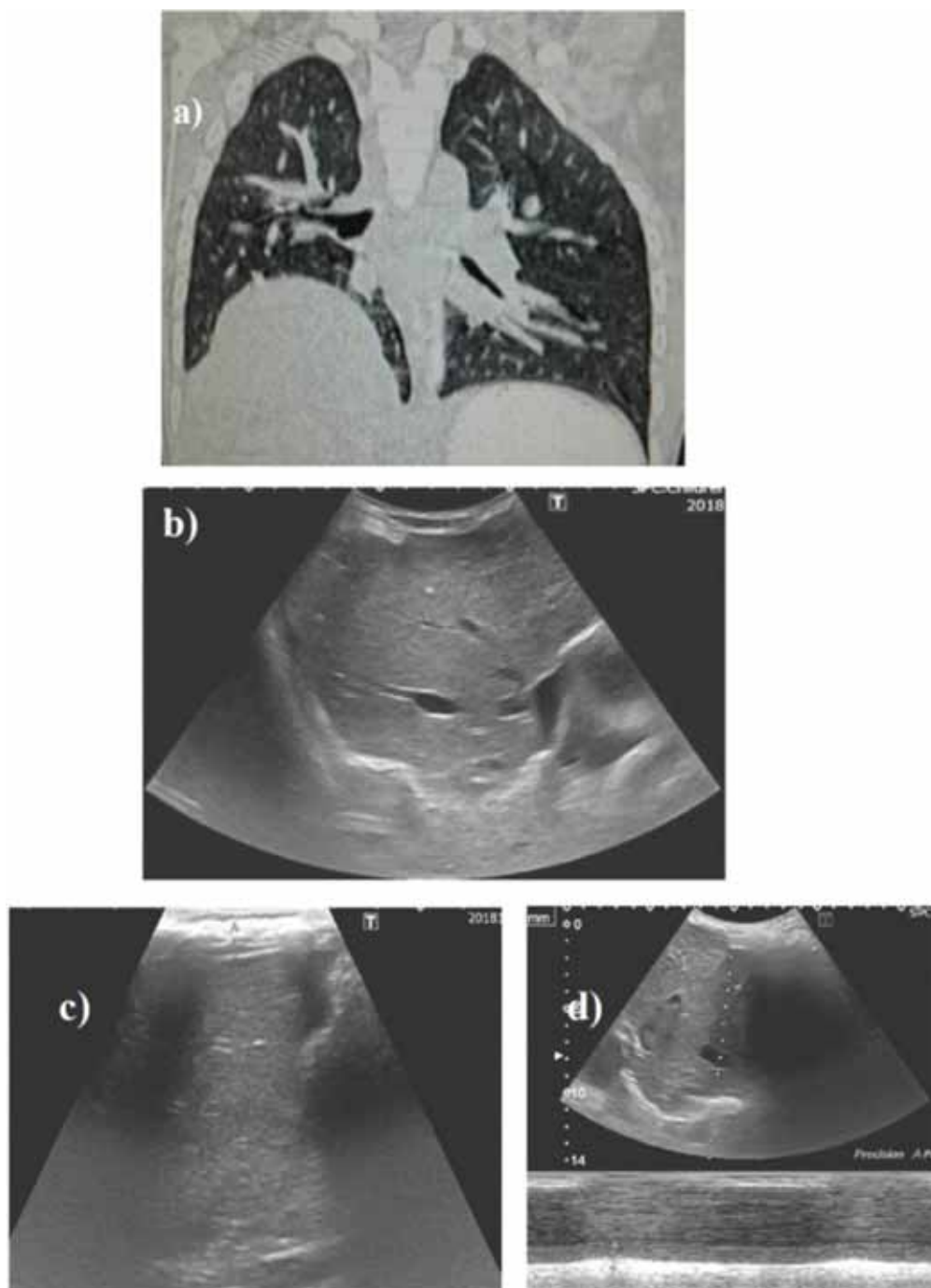
Sonographic findings	Number of cases (%)
Morphological features	
Thickness changes	
Thickened diaphragm	5 (12.2)
Thinned-out diaphragm	2 (4.9)
Defects	
Congenital	2 (4.9)
Acquired	3 (7.3)
Functional abnormalities	
Weakness	10 (24.4)
Paralysis	9 (21.95)

Elevated diaphragmatic copula was documented in 20 (48.8%) patients. This was either due to intrinsic diaphragmatic abnormality or infradiaphragmatic causes (Table 2).

Discussion

The diaphragm is the major respiratory muscle. Dysfunction of the diaphragm is an underappreciated cause of respiratory difficulties and may be due to a wide variety of entities, including conditions either directly involving the diaphragm, or adjacent thoracic or abdominal pathology. Diaphragmatic disease usually manifests as elevation at chest radiography. Imaging of the diaphragm can be anatomic or functional. Although all radiologic modalities can be used for anatomic imaging, functional imaging is mainly performed with fluoroscopy, ultrasonography, and MR fluoroscopy [9]. US imaging allows a noninvasive, radiation-free, accurate, reproducible, and safe assessment of diaphragm anatomy and function [10]. The purpose of this study was to assess the role of US in evaluation of the diaphragm, assessing normal diaphragm or any abnormality detected

Figure 4



A 6-year case presented with elevated right hemidiaphragm. (a) Computed tomography chest showing elevated right copula; (b) ultrasound image intercostal view showing abnormal focal bulge of anteromedial aspect of right hemidiaphragm; (c) intercostal view showing abnormal focal thinning out of right hemidiaphragm (1.7 mm) with TF (22%); (d) intercostal view showing limited diaphragmatic movement in normal breathing (0.8 cm), deep breathing (1.8 cm), and sniff test (1 cm). Diagnosis: dromedary hump of right hemidiaphragm with ipsilateral diaphragmatic weakness.

through assessing its morphology, integrity, thickness, and measuring different parameters, also aiming for proper assessment of supradiaphragmatic or infradiaphragmatic lesions that affect the diaphragm. This study involved performing diaphragmatic US of 118 patients who were referred to the US Radiology Unit and Chest Department in Kasr Al-Ainy Hospital.

The cases were grouped into two groups, those with normal US findings of the diaphragm represented group A, while patients with any diaphragmatic abnormality were represented by group B. Group A includes 77 (65.25%) patients, (37 men, 40 women) with age range from 2 to 75 years (mean age of 31 years). In this group there were normal diaphragm morphology with normal parameters and no defect

Table 2 Causes of elevated diaphragmatic copula among the study patients

Sonographic findings (cause of elevated copula)	Number of cases	Affected side	
		Right	Left
Intrinsic diaphragmatic abnormality			
Diaphragmatic hernia	2	–	2
Diaphragmatic hump	1	1	–
Diaphragmatic weakness	3	2	1
Diaphragmatic paralysis	7	2	5
Infradiaphragmatic causes			
Abdominal collection	5	3	2
Subphrenic abscess	2	2	–

Patients with elevated diaphragmatic copula were 20 (48.8%) cases out of 41 patients with diaphragmatic abnormality.

detected or supra/infradiaphragmatic lesions. Group B includes 41 (34.75%) patients (six women, 35 men) with age range from 2 to 83 years (mean age of 40.78 years) and involve patients with intrinsic and extrinsic diaphragmatic abnormalities. Intrinsic abnormalities were detected in 23 patients (56.09%; five women and 18 men) out of the 41 patients with diaphragmatic abnormalities in the age range from 2 to 73 years (mean age of 30.4 years). Intrinsic abnormalities were either in morphological features of the diaphragm (thickness changes/integrity defect) or in function which was detected by dynamic US. Five cases out of 41 (12.2%) were found to have thickened diaphragm, four out of these five cases showed malignant infiltration of the diaphragm either metastatic or by mesothelioma. Two cases out of 41 (4.9%) were found to have thinned-out diaphragm (a case of chronically paralyzed atrophic diaphragm and another with a dromedary hump). Also two (4.9%) cases showed congenital diaphragmatic defect and another three (7.3%) cases showed acquired diaphragmatic defect. Ten (24.4%) cases showed diaphragmatic weakness and nine (21.95%) cases showed diaphragmatic paralysis (7.6%). Extrinsic abnormalities affecting the diaphragm were found in 19 out of the 41 patients (46.34%) (nine women, 10 men) with age range from 6 to 83 years (mean age of 53.6 years) were either supradiaphragmatic or infradiaphragmatic or both.

The following parameters were recorded in this study:

Normal diaphragmatic thickness

In this study diaphragmatic thickness ranged from 1.8 to 3 mm with the mean thickness being 2.3 mm. Mean thickness of the right hemidiaphragm was 2.37 mm while mean thickness of the left hemidiaphragm was

2.23 mm. Thinned-out/atrophic diaphragm was defined when the diaphragm thickness was less than 1.8 mm. Thickened diaphragm was defined when diaphragm thickness was more than 3 mm.

Goligher *et al.* [11] stated that diaphragm thickness depends on muscle mass and reduced diaphragm thickness may indicate presence of atrophy. Diaphragm thickness can be quantified simply using ultrasonography, with the right hemidiaphragm, through the hepatic window, it being more accessible than the left. Normal diaphragm thickness in ventilated patients is 2.4 ± 0.8 mm, with atrophy defined as values less than 2 mm. Ratios of 1.8 are considered normal, with a lower accepted limit of 1.2 mm. The study was done through five observers measured T_{di} and TF_{di} in 96 mechanically ventilated patients and nine healthy volunteers. They concluded that diaphragmatic US can be reliably used to monitor diaphragm thickness, activity, and function during mechanical ventilation.

McCool *et al.* [12] stated that the average thickness of the diaphragm is 0.22–0.28 cm in healthy volunteers and 0.13–0.19 cm in a paralyzed diaphragm. A diaphragm thickness less than 0.2 cm has been proposed as the cutoff to define diaphragm atrophy.

US parameters of thickness can vary depending on the site of measurement and the initial point of measurement being end expiration or beginning of inspiration [13].

The measurement of thickness alone may miss an acutely paralyzed diaphragm with normal thickness and could incorrectly identify atrophy in a low-weight individual with a healthy, yet thin diaphragm. Therefore, the degree of diaphragm thickening has been proposed to be more sensitive than measurement of thickness alone [8].

Normal thickening fraction

Muscle fibers shorten with contraction and cause muscle thickening. Increase in diaphragmatic thickness during inspiration has been used as an indirect measurement of muscle fiber contraction which is measured through the general formula: (thickness at end inspiration–thickness at end expiration)/thickness at end expiration [7]. In this study, diaphragm TF ranged from 22 to 78% with a mean TF of 38.4%. Mean TF of the right hemidiaphragm was 35.4% while the mean TF of the left hemidiaphragm was 41.4%.

Gottesman *et al.* [7] stated that a change in diaphragm thickness of 28–96% has been reported in healthy volunteers, with a change of –35% to 5% in those with a paralyzed diaphragm. This study involved 30 participants who had diaphragm US performed to evaluate for paralyzed diaphragm (five with bilateral diaphragm paralysis, seven with unilateral diaphragm paralysis, three with inspiratory weakness but normally functioning diaphragms, and 15 healthy volunteers as controls). They concluded that US measurements of $T_{(di)}$ and $TF_{(di)}$ can be used to determine if a diaphragm is paralyzed and confirm their predictions that a chronically paralyzed diaphragm is atrophic and does not thicken during inspiration.

Jung *et al.* [14] concluded that a thickness variation of less than 20% may be considered as a predictor for failure to weaning from mechanical ventilation. Among 185 consecutive patients ventilated for more than 48 h, diaphragm dysfunction was observed with ICU-acquired diaphragmatic weakness in 32 patients. Diaphragm function was assessed using several parameters including sonographically recorded TF.

Also, Farghaly *et al.* [15] reported a significant decrease in T_{di} at end expiration by approximately 27.2% on the third day of MV among their patients and on the fifth day; a continuous decrease in T_{di} at end expiration by 35.5% was reported. Even in patients who were still mechanically ventilated till the seventh day, T_{di} at end expiration was significantly lower compared with baseline recordings.

El Naggara *et al.* [16] concluded in their work that diaphragmatic US parameters provide rapid and noninvasive indices for weaning process with high accurate results in comparison with other traditional indices such as blood gases and the respiratory mechanics. Therefore, they can be used as predictive parameters to assess the weaning process outcome.

Normal diaphragmatic excursion

In this study, excursion in normal breathing ranged from 0.9 to 3.6 cm with a mean of 2 cm. Mean excursion for the right hemidiaphragm was 1.85 cm and mean excursion for the left hemidiaphragm was 2.31 cm. Excursion in deep breathing ranged from 2 to 11.9 cm with a mean of 5.9 cm. Mean excursion for the right hemidiaphragm was 5.1 cm while mean excursion for the left hemidiaphragm was 6.7 cm. Excursion in sniffing ranged from 1.4 to 11.5 cm with a mean of 4.25 cm. Mean excursion for the right hemidiaphragm was 3.5 cm while mean for the left hemidiaphragm

being 5 cm. Diaphragm weakness is indicated by a less than normal amplitude of excursion on deep breathing with or without paradoxical motion on sniffing. Diaphragmatic paralysis is indicated by the absence of excursion with quiet and deep breathing and with absence of movement or paradoxical motion upon sniffing.

The measurement of excursion depends on maximal voluntary inspiratory effort. This limits the interpretation and generalization of cutoff values of excursion amplitudes in heterogeneous populations [17].

Boussuges *et al.* [18] studied 210 participants (150 men, 60 women, 50±14 years) who were investigated through an observational study; they assumed these normal values of diaphragmatic excursion:

	Quiet breathing	Deep breathing	Sniffing
Normal values (cm)	1.5–2	6–7	2.5–3
Lower values (cm)	0.9	3.5	1.6

They demonstrated that M-mode ultrasonography is a reproducible method for assessing hemidiaphragmatic movement.

In conclusion, diaphragmatic US is a noninvasive, portable, quick to perform, simple, and well-tolerated test that provides real-time image. In addition, there is no exposure to ionizing radiation. Thus, US has been suggested as the technique of choice for assessing diaphragmatic movement on suspicion of malfunctioning. Ultrasonography is a promising technique for structural and functional evaluation of the diaphragm. It is accurate, reproducible, and relatively easy to learn. It is portable, which is very important for critically ill patients on mechanical ventilation. Multiple studies have reported ultrasonography as the modality of choice for evaluation of diaphragm paralysis, especially in neonatal, pediatric, and critically ill patients.

US have some potential limitations, being operator dependent, the measurement of excursion depends on maximal voluntary inspiratory effort which limits the interpretation and generalization of cutoff values of excursion amplitudes in heterogeneous populations and lack of reference values for diaphragm parameters in patients with pulmonary or neuromuscular disease, because they have different ranges of lung volumes for quiet breathing, deep breathing, or sniff maneuvers.

Finally, we recommend that imaging protocols should be developed and validated to standardize ultrasonographic assessment of the diaphragm including identification of diaphragm paralysis, identification of etiology of diaphragm paralysis including intrinsic and extrinsic diaphragmatic abnormalities, prognosis after diaphragm paralysis (in patients with serial US measurements after diaphragm paralysis, an increase in thickness of the diaphragm during inspiration, probably correlates with reinnervations, also associated with improvement in inspiratory function over time), assessment of weaning failure (TF is a proper indicator for this), postoperative (after thoraco-abdominal surgeries) M mode ultrasonography of the diaphragm which is a clinical tool to predict changes in pulmonary function as spirometry may not be a practical tool in such patients, and lastly identification of traumatic diaphragmatic rupture as an extension of the 'focused abdominal sonography for trauma' examination.

Acknowledgements

This study was conducted as a collaboration between the Departments of Pulmonary Medicine and Radiology to enhance the utility of ultrasonography as a powerful tool for the diagnosis of morphological and functional diaphragmatic abnormalities.

Financial support and sponsorship

Nil.

Conflicts of interest

There are no conflicts of interest.

References

- 1 Yeh HC, Halton KP, Gray CE. Anatomic variations and abnormalities in the diaphragm seen with US. *Radiographics* 1990; **10**:1019–1030.
- 2 Sarwal A, Walker FO, Cartwright MS. Neuromuscular ultrasound for evaluation of the diaphragm. *Muscle Nerve* 2013; **47**:319–329.
- 3 Gerscovich EO, Cronan M, McGahan JP, Jain K, Jones CD, McDonald C. Ultrasonographic evaluation of diaphragmatic motion. *J Ultrasound Med* 2001; **20**:597–604.
- 4 Chavhan GB, Babyn PS, Cohen RA, Langer JC. Multimodality imaging of the pediatric diaphragm: anatomy and pathologic conditions. *Radiographics* 2010; **30**:1797–1817.
- 5 Houston JG, Morris AD, Howie CA, Reid JL, Mcmillan N. Technical report: quantitative assessment of diaphragmatic movement – a reproducible method using ultrasound. *Clin Radiol* 1992; **46**:405–407.
- 6 Epelman M, Navarro OM, Daneman A, Miller SF. M-mode sonography of diaphragmatic motion: description of technique and experience in 278 pediatric patients. *Pediatr Radiol* 2005; **35**:661–667.
- 7 Gottesman E, Mc Cool FD. Ultrasound evaluation of the paralyzed diaphragm. *Am J Respir Crit Care Med* 1997; **155**:1570–1574.
- 8 Summerhill EM, El-Sameed YA, Glidden TJ, McCool FD. Monitoring recovery from diaphragm paralysis with ultrasound. *Chest* 2008; **133**:737–743.
- 9 Nason LK, Walker CM, McNeeley MF, Burivong W, Fligner CL, Godwin JD. Imaging of the diaphragm: anatomy and function. *Radiographics* 2012; **32**:E51–E70.
- 10 Boon AJ, Harper CJ, Ghahfarokhi LS, Strommen JA, Watson JC, Sorenson EJ. Two-dimensional ultrasound imaging of the diaphragm: quantitative values in normal subjects. *Muscle Nerve* 2013; **47**:884–889.
- 11 Goligher EC, Laghi F, Detsky ME, Farias P, Murray A, Brace D, et al. Measuring diaphragm thickness with ultrasound in mechanically ventilated patients: feasibility, reproducibility and validity. *Intensive Care Med* 2015; **41**:642–649.
- 12 McCool FD, Tzelepis GE. Dysfunction of the diaphragm. *N Engl J Med* 2012; **366**:932–942.
- 13 Kantarci F, Mihmanli I, Demirel MK, Harmanci K, Akman C, Aydogan F, et al. Normal diaphragmatic motion and the effects of body composition: determination with M-mode sonography. *J Ultrasound Med* 2004; **23**:255–260.
- 14 Jung B, Moury PH, Mahul M, de Jong A, Galia F, Prades A, et al. Diaphragmatic dysfunction in patients with ICU-acquired weakness and its impact on extubation failure. *Intensive Care Med* 2016; **42**:853–861.
- 15 Farghaly S, Hasan AA, Makhlof HA. Assessment of ventilator-induced diaphragmatic dysfunction in patients with chronic obstructive pulmonary disease using transthoracic ultrasonography. *Egypt J Bronchol* 2018; **12**:218–225.
- 16 El Naggara TA, Dwedara IA, Abd-Allah EFA. Diaphragm ultrasound as a predictor of successful extubation from mechanical ventilation. *Egypt J Bronchol* 2019; **13**:191–195.
- 17 Lerolle N, Guérot E, Dimassi S, Zegdi R, Faisy C, Fagon JY, et al. Ultrasonographic diagnostic criterion for severe diaphragmatic dysfunction after cardiac surgery. *Chest* 2009; **135**:401–407.
- 18 Boussuges A, Gole Y, Blanc P. Diaphragmatic motion studied by m-mode ultrasonography: methods, reproducibility, and normal values. *Chest* 2009; **135**:391–400.