

# Submandibular salivary gland involvement in granulomatosis with polyangiitis

Mohamed F. Abdelghany, Mohammad G.A. Khalaf

**Introduction** Granulomatosis with polyangiitis (GPA) is one of the forms of small vessel vasculitis. It is a rare condition that needs a high degree of suspicion to reach the diagnosis. It is one of the causes of diffuse parenchymal lung disease, with a very wide differential diagnosis. It is commonly misdiagnosed with malignant, granulomatous, and infectious lung diseases.

**Case presentation** We report a case of a 31-year-old male who presented with productive cough, shortness of breath, hemoptysis, nasal obstruction, and epistaxis together with submandibular salivary gland swelling. Diagnosis of GPA was based on characteristic cavitary lung lesions, nasal and salivary gland involvement, pathological samples that revealed necrotizing granulomatous inflammation, characteristic positive Cytoplasmic- ANCA (C-ANCA), together with exclusion of malignancy and tuberculosis.

**Conclusion** GPA is a rare condition. Salivary gland involvement should raise suspicion about GPA, in addition to other systemic manifestations.

## Introduction

Granulomatosis with polyangiitis (GPA) is one of the forms of small vessel vasculitis. It was renamed GPA instead of the old name, 'Wegener's granulomatosis,' according to revised international Chapel Hill international consensus [1]. It is a rare condition in which diagnosis is difficult, owing to multisystem affection. GPA commonly overlaps with other conditions such as neoplastic, infectious, and connective tissue diseases. Systems commonly involved are ENT, lung, and kidney. Salivary gland involvement is rarely encountered in patients with GPA [2]. It has been described in a small number of case reports and case series [3–9].

## Case report

A 31-year-old male was admitted to hospital owing to productive cough, occasional hemoptysis, and progressive dyspnea of 6-week duration. He complained of low-grade fever, malaise, and weight loss as well from the same duration. He had nasal obstruction and recurrent epistaxis, which was managed conservatively. He noted painless neck swelling from 1 month. The patient received empirical antibiotic treatment before admission to the hospital with no response. He is not known to be diabetic or hypertensive. He was a mild cigarette smoker. He was admitted for respiratory distress. On examination, his BMI was 29 kg/m<sup>2</sup>, not toxic. His vital signs were unremarkable. Head and neck

*Egypt J Bronchol* 2019 13:781–785

© 2020 Egyptian Journal of Bronchology

*Egyptian Journal of Bronchology* 2019 13:781–785

**Keywords:** ANCA, granulomatosis with polyangiitis, salivary gland, Wegener's, granulomatosis

Department of Chest Diseases, Faculty of Medicine, Assiut University, Assiut, Egypt

Correspondence to Mohammad G.A. Khalaf, MD, Department of Chest Diseases, Faculty of Medicine, Assiut University Hospital, Assiut University, Assiut 71515 Egypt. Tel: +20 882 413 709; fax: +20882333327 (Hospital Fax); e-mail: dr.mga2011@au.edu.eg

**Received:** 18 February 2019 **Accepted:** 16 July 2019

**Published:** xx xx 2020

examination revealed bilateral submandibular swellings. Both were nontender, solid, firm in consistency, as well as multiple enlarged cervical lymph nodes. His chest examination revealed signs of respiratory distress, with inspiratory wheeze, increased tactile vocal fremitus, increased vocal resonance, and medium sized crepitations on the right mammary area.

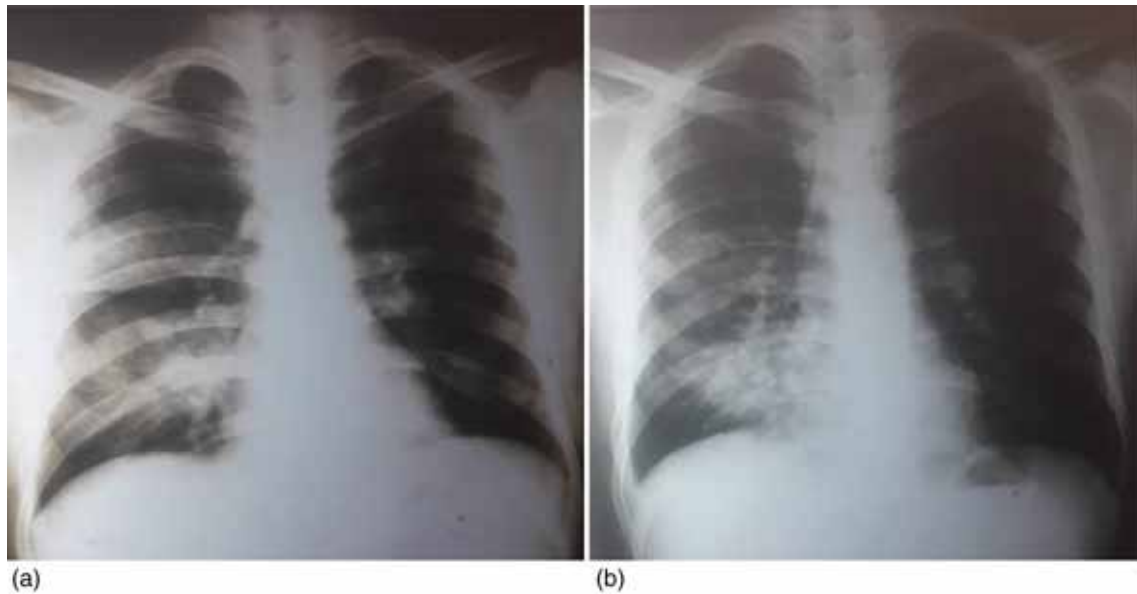
Chest radiograph showed semihomogenous opacity in the middle and lower lung zones on the right side. At that time, the working diagnosis was atypical pneumonia. Accordingly, he was treated with antibiotic combinations. Follow-up chest radiograph 10 weeks later revealed persistence of the described opacity (Fig. 1a and b). Computed tomography (CT) chest revealed focal consolidation affecting the right middle lobe and the medial basal segment of the right lower lobe with air bronchogram seen inside. Multiple rounded nodules were seen in both lower lobes with ill-defined margin and central cavitation. No mediastinal or hilar lymph nodes were seen (Fig. 2).

Repeated sputum samples were negative for acid-fast bacilli (AFB). Gene Expert test was done from sputum

---

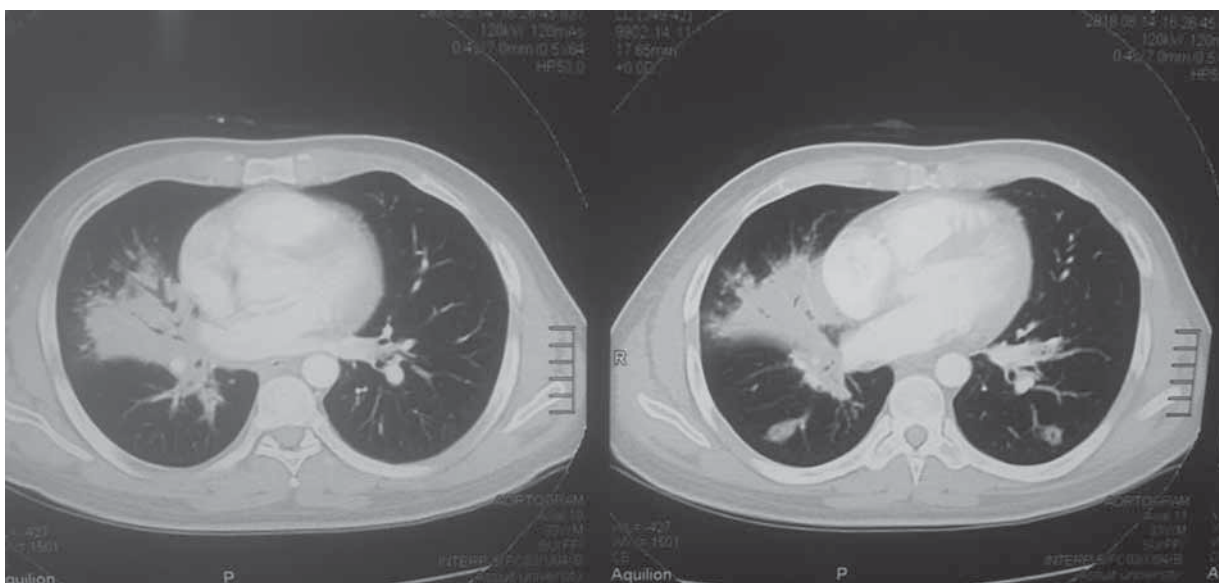
This is an open access journal, and articles are distributed under the terms of the Creative Commons Attribution-NonCommercial-ShareAlike 4.0 License, which allows others to remix, tweak, and build upon the work non-commercially, as long as appropriate credit is given and the new creations are licensed under the identical terms.

Figure 1



Chest radiograph. (a) Chest radiograph at presentation and (b) chest radiograph 10 weeks later shows persistent area of lung consolidation.

Figure 2



Computed tomography chest.

and was also negative. Erythrocyte Sedimentation Rate (ESR) at first hour was 104 ml/h and at second hour was 122 ml/h. On follow-up, mm/hr at first hour was 103 ml/h and at second hour was 119 ml/h. White Blood Cells (WBC) was  $6.6 \times 10^3 \mu/l$ , Hemoglobin (Hb) was 10.5 g/dl, and Platelets (PLT) was  $434 \times 10^3 \mu/l$ . Urea, creatinine, and liver function test results were normal. Arterial Blood Gases (ABG) results revealed the following: pH: 7.54,  $CO_2$ : 34 mmHg,  $PO_2$ : 69 mmHg, and  $HCO_3$ : 28 mmol/l. Spirometry showed very severe obstructive

dysfunction (post-bronchodilator Forced Expiratory Volume in 1 second ( $FEV_1$ )=27 %predicted).

Abdomino-pelvic ultrasound examination and echocardiography were normal. ENT examination revealed marked septum deviation to the left side, atrophic rhinitis, and marked crustation. Oropharyngeal examination revealed 'uvula sign'. Laryngeal examination revealed bilateral freely mobile vocal folds. Biopsy from inferior turbinate was taken to exclude rhinoscleroma. It revealed

hyperplastic covering epithelium with infiltration of subepithelial tissue by chronic nonspecific lymphohistiocytic inflammatory cells admixed with fibrous tissue. No evidence of neoplasia was found. Geimsa stain was negative for *Klebsilla rhinoscleromatis*.

Neck Ultrasonography (US) revealed diffuse submandibular gland swelling with preserved architecture but no malignant features, as well as enlarged submandibular lymph nodes measuring 3 cm in greatest dimension with preserved architecture.

US-guided Fine Needle Aspiration Cytology (FNAC) from cervical lymph node revealed hypercellular smears featuring epithelioid cells, existing in syncytial form, displaying disorderly arranged carrot-shaped nuclei, with fine granular chromatin. Background showed granular debris admixed with numerous polymorphonuclear leukocytes (PMNLs) and red blood cells. Ziehl–Neelsen stain was negative for AFB. Periodic acid Schiff result was negative for fungi. The sample was negative for malignancy. The pathologist diagnosis was suppurative granulomatous lymphadenitis.

Multislice Computed Tomography (MSCT) neck disclosed bilateral diffuse submandibular gland

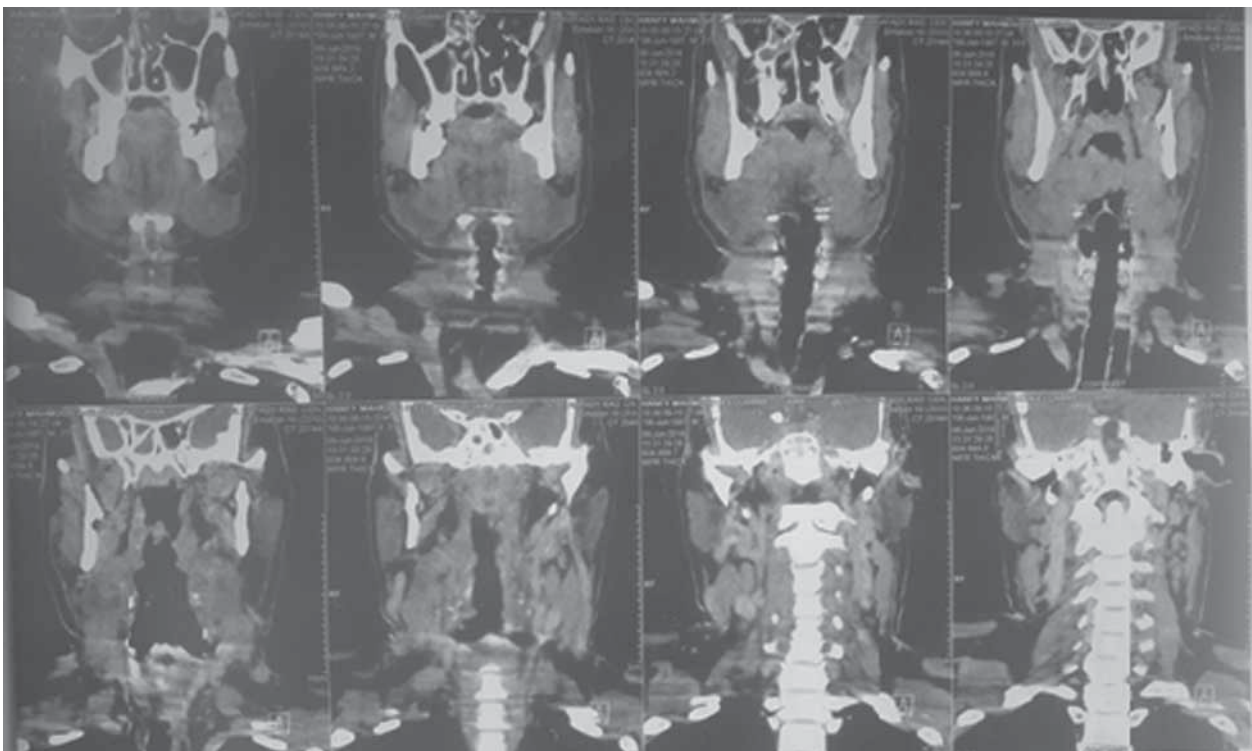
enlargement, with edematous changes. No definite mass lesions were detected. Normal appearance of parotid glands. Mild enlarged cervical lymph nodes, with preserved pattern (Fig. 3).

Bronchoscopy revealed congested, ulcerated, and discolored bronchial mucosa covered by widespread white patches and purulent secretions, with scarring and distortion of bronchial tree. The right upper lobe bronchus was narrowed, and further segmental bronchi could not be seen. The intermediate bronchus was also narrowed and distorted, with irregular mucosa. Broad carina was observed between intermediate bronchus and right upper lobe bronchi, as well as between left upper lobe and left lower lobe bronchi.

Multiple bronchoscopic biopsies were taken from these lesions, which revealed infiltration of the lamina propria by chronic inflammatory cells, areas of necrotizing inflammation infiltrated by PMNLs and pus cells, and squamous metaplasia of the covering respiratory mucosa.

Bronchial wash and brush disclosed bronchial epithelial cells, metaplastic squamous cells, alveolar macrophages, large number of PMNLs, pus cells, and necrotic cells. Bronchial wash was negative for AFB.

Figure 3



Computed tomography neck.

Cultures from sputum and bronchial wash were positive for fungi. The patient received micafungin 100 mg/day infusion for 10 days with no improvement.

Rheumatoid factor titer was shooting ( $>128$  U/ml). Antinuclear antibody was negative (0.35 IU/ml). Anti-double strand DNA (anti-DS DNA) was borderline (0.9 U/ml) (negative  $<0.9$  U/ml, positive  $>1.1$  U/ml). The characteristic association of pulmonary and nasal involvement, together with characteristic cavitating consolidation evident in CT chest raised the suspicion of systemic vasculitis. Serum Antinuclear Cytoplasmic Antibodies (ANCA) was done. C-ANCA was positive (11.7, normal  $<5$  U/ml). P-ANCA was negative (0.29 U/ml).

## Discussion

GPA is one of ANCA-associated vasculitides. It is frequently associated with cytoplasmic pattern (antiproteinase-3 antibodies) [10]. It is characterized pathologically by necrotizing granulomatous inflammation [11] as evident in this case in multiple pathological samples taken from lymph nodes, nose, bronchi, and submandibular salivary glands. Affection of salivary glands is an atypical presentation of GPA. The rarity of salivary gland involvement in GPA drove us to think in malignancy or tuberculosis as first possibilities, which are far more prevalent. The repeated samples excluding these two provisional diagnoses, together with characteristic cavitating lung nodules and consolidation, and nasal involvement made us think about GPA. The absence of renal affection does not preclude GPA. Renal involvement in GPA ranges from 85 to 59% in different studies [12,13]. Patients with limited disease can present without renal affection. Early diagnosis and treatment of such cases can effectively limit disease progression, induce remission, and prevent fatal renal sequelae.

GPA commonly affects adult males [13], as in the present case. Approximately 90% of patients with active, generalized disease have positive C-ANCA [14]. The sensitivity of c-ANCA reaches 96% in systemic form of GPA [15].

Salivary gland enlargement can occur owing to many infectious, autoimmune, iatrogenic, granulomatous, and neoplastic effects [4]. If salivary gland enlargement occurred with other organ affection, a systemic cause should be suspected.

This case presentation reports this uncommon presentation of GPA, bilateral submandibular salivary gland enlargement. The parotid gland is the most common among salivary gland involvement in GPA. Bilateral submandibular salivary gland affection is described in a few case reports [2]. On the contrary, salivary gland involvement in GPA may be underestimated. The use of combined CT-PET scan can aid in detection of the degree of organ affection in multisystem disease [16].

The present case highlights the importance of multidisciplinary approach in reaching final diagnosis. Co-operation, discussions, and coalescence between different specialties (pulmonology, ENT, clinical pathology, maxillofacial surgery, nephrology, and rheumatology) are mandatory to diagnose this category of patients with multisystem involvement.

## Conclusion

Salivary gland involvement in GPA is uncommon. Early diagnosis and prompt management is important to limit disease progression and prevent complications.

## Acknowledgements

The authors would like to present their appreciation to the residents who helped us in data collection.

## Financial support and sponsorship

Nil.

## Conflicts of interest

There are no conflicts of interest.

## References

- Jennette JC, Falk RJ, Bacon PA, Basu N, Cid MC, Ferrario F, et al. 2012 revised international chapel hill consensus conference nomenclature of vasculitides. *Arthritis Rheum* 2013; **65**:1–11.
- Barrett AW. Wegener's granulomatosis of the major salivary glands. *J Oral Pathol Med* 2012; **41**:721–727.
- Chegar BE, Kelley RT. Wegener's granulomatosis presenting as unilateral parotid enlargement. *Laryngoscope* 2004; **114**:1730–1733.
- Gassling V, Wiltfang J, Hampe J, Braesen JH, Both M, Moosig F. Salivary gland swelling in Wegener's granulomatosis: a rare cause of a frequent symptom. *J Rheumatol* 2010; **37**:2633–2635.
- Saravanappa N, Bibas A, Singhal A, Davis JP. Unilateral parotid swelling as initial manifestation of Wegener's granulomatosis. *J Otolaryngol* 2000; **29**:396–367.
- Garcia-Porrúa C, Amor-Dorado JC, Gonzalez-Gay MA. Unilateral submandibular swelling as unique presentation of Wegener's granulomatosis. *Rheumatology* 2001; **40**:953–954.
- Frantz MC, Frank H, von Weyhern C, Kiefer J. Unspecific parotitis can be the first indication of a developing Wegener's granulomatosis. *Eur Arch Otorhinolaryngol* 2008; **265**:131–134.

- 8 Ceylan A, Asal K, Çelenk F, Köybaşıoğlu A. Parotid gland involvement as a presenting feature of Wegener's granulomatosis. *Singapore Med J* 2013; **54**:e196–e198.
- 9 Geyer M, Kulamarva G, Davis A. Wegener's granulomatosis presenting with an abscess in the parotid gland: a case report. *J Med Case Rep* 2009; **3**:19.
- 10 Pagnoux C. Updates in ANCA-associated vasculitis. *Eur J Rheumatol* 2016; **3**:122.
- 11 Wojciechowska J, Krajewski W, Krajewski P, Króćicki T. Granulomatosis with polyangiitis in otolaryngologist practice: a review of current knowledge. *Clin Exp Otorhinolaryngol* 2016; **9**:8–13.
- 12 Reinhold-Keller E, Beuge N, Latza U, De Groot K, Rudert H, Nölle B, et al. An interdisciplinary approach to the care of patients with Wegener's granulomatosis: long-term outcome in 155 patients. *Arthritis Rheum* 2000; **43**:1021–1032.
- 13 Jokar M, Mirfeizi Z. Granulomatosis with polyangiitis (Wegener's granulomatosis): an analysis of 59 patients. *Rheumatol Res* 2017; **2**:115–118.
- 14 Hoffman GS, Pecks U. Antineutrophil cytoplasmic antibodies. *Arthritis Rheum* 1998; **41**:1521–1537.
- 15 Nolle B, Specks U, Lüdemann J, Rohrbach MS, DeRemee RA, Gross WL. Anticytoplasmic autoantibodies: their immunodiagnostic value in Wegener granulomatosis. *Ann Intern Med* 1989; **111**:28–40.
- 16 Almuhaideb A, Syed R, Iordanidou L, Saad Z, Bomanji J. Fluorine-18-fluorodeoxyglucose PET/CT rare finding of a unique multiorgan involvement of Wegener's granulomatosis. *Br J Radiol* 2011; **84**: e202–e204.