

Spontaneous pneumothorax: time to depart from the ‘chest tube underwater seal’?

Maged Hassan^{a,b}, Hany Shaarawy^b,

Initial management of spontaneous pneumothorax has traditionally been inserting a chest tube and attaching it to an underwater seal and hospitalizing the patient. New options have emerged that allow management to be on an outpatient basis without the need for hospitalization. These options are needle aspiration (similar to aspiration of effusion) or attaching the chest tube to a one-way valve. So, is chaining a patient with spontaneous pneumothorax to their hospital bed because of the heavy jar attached to the chest tube the most prudent way of management? This review attempts to answer this question.

Egypt J Bronchol 2018 12:137–142

© 2018 Egyptian Journal of Bronchology

Introduction

Pneumothorax is the abnormal collection of air in the pleural space. The earliest report of the condition dates back to an account made by an Ottoman physician in the 15th century AD of a case of traumatic pneumothorax [1]. Pneumothorax is termed ‘spontaneous’ when it is not precipitated by any type of injury. Pneumothorax can occur as a complication of invasive medical procedures (iatrogenic) or a blunt or penetrating trauma to chest wall (traumatic) [2]. Spontaneous pneumothorax (SP) is divided into primary spontaneous pneumothorax (PSP) or secondary spontaneous pneumothorax (SSP), depending on the presence or lack of structural lung diseases and/or significant smoking history [3].

The initial management of SP is centered on evacuation of pleural air; the necessity and urgency of which depends on the size of the pneumothorax, the patient’s degree of symptoms, the presence of structural lung disease, and the general condition of the patient [4]. A small PSP in a stable patient without-dyspnea can usually be safely observed [3,5]. It is estimated that a pneumothorax will resolve at a rate of 1.5–2% of its volume per day as long as air leak has ceased [6]. SP has the tendency to recur with a 1-year recurrence rate of 20–50% in PSP [7]. For this reason, recurrence prevention is a crucial component in the management of PSP and SSP at the first recurrence. Recurrence prevention is occasionally indicated during the first incidence of pneumothorax if a recurring pneumothorax is feared to have serious consequences to a patient’s well-being [3,4]. This review will focus on the initial management of SP. Recurrence prevention is extensively covered elsewhere.

Egyptian Journal of Bronchology 2018 12:137–142

Keywords: chest tube, Heimlich valve, needle aspiration, pneumothorax, practice guidelines

^aCentre for Respiratory Medicine, Oxford University Hospitals, Oxford, UK,

^bDepartment of Chest Diseases, Faculty of Medicine, Alexandria University, Alexandria, Egypt

Correspondence to Maged Hassan, MSc, Oxford Centre for Respiratory Medicine, Churchill Hospital, Old Road, Headington OX3 7LE, Oxford, UK; Tel: +44 796 035 7965; fax: +44(0) 1865 857109; e-mail: maged.fayed@ouh.nhs.uk

Received 1 July 2017 **Accepted** 13 August 2017

The traditional means of drainage of pleural air is by inserting a rubber/silicone drain in an intercostal space and connecting it to an underwater seal. This is generally a safe procedure, but it makes the hospital admission inevitable, imposing significant costs in terms of hospital stay. In addition, connecting a chest tube to the underwater seal obliges the patient to be relatively immobile which is a risk factor for venous thromboembolism [8]. This is especially true for older patients who have other risk factors. Emergency department management of pneumothorax in addition to outpatient follow-up has been contemplated and tested by many as a means to address this problem.

The paradigm shift

The concept of catheter aspiration for simple pneumothorax (CASP) was first suggested in 1962 by Klassen *et al.* [9]. It emerged as a method of handling pneumothorax in a similar fashion to how chest physicians deal with pleural effusion. This nascent practice was criticized at the time owing to fear of imminent risk of lung laceration by the aspirating needle [10]. Since then, many case series have contested the claim that chest tube underwater seal is the only safe means for pneumothorax drainage and refuted the perceived risk of iatrogenic lung trauma [8,11,12]. These reports have examined CASP in the setting of spontaneous and traumatic pneumothoraces.

This is an open access journal, and articles are distributed under the terms of the Creative Commons Attribution-NonCommercial-ShareAlike 4.0 License, which allows others to remix, tweak, and build upon the work non-commercially, as long as appropriate credit is given and the new creations are licensed under the identical terms.

Around the same period, Bernstein *et al.* [13] suggested the possibility of outpatient management of pneumothorax by replacing the underwater seal with a one-way valve (called Heimlich valve) attached to the chest tube. This modification allowed patients to be discharged within hours of putting in the chest tube and maintained their mobility owing to the lack of the heavy jar used to create the underwater seal. This method of management has been termed 'ambulatory management' of pneumothorax [4,14].

Needle aspiration

The evidence

Early studies suggested the safety of CASP, but evidence of its efficacy was more recently proved by successive randomized controlled trials (RCTs) [4]. The largest RCT on needle aspiration for PSP was conducted by Ayed *et al.* [15] who randomized 137 patients to either needle aspiration or chest tube drainage. The immediate success rate was 62% for needle aspiration compared with 68% success for chest tube drainage (difference not statistically significant) [15]. Other RCTs reported success rates between 60 and 70% for simple aspiration [16,17]. To put matters in perspective, this means that avoiding admission is possible in seven of every 10 patients presenting with a symptomatic PSP. A 2007 Cochrane Review concluded that there was no significant difference in the success rates for needle aspiration versus chest tube drainage for patients presenting with PSP [18]. The review also pointed out that needle aspiration was found to be associated with fewer hospitalizations. This compelling evidence led the British Thoracic Society (BTS) 2010 guidelines to adopt needle aspiration as plausible management option for SP as long as enough expertise in the procedure is available (see below) [3].

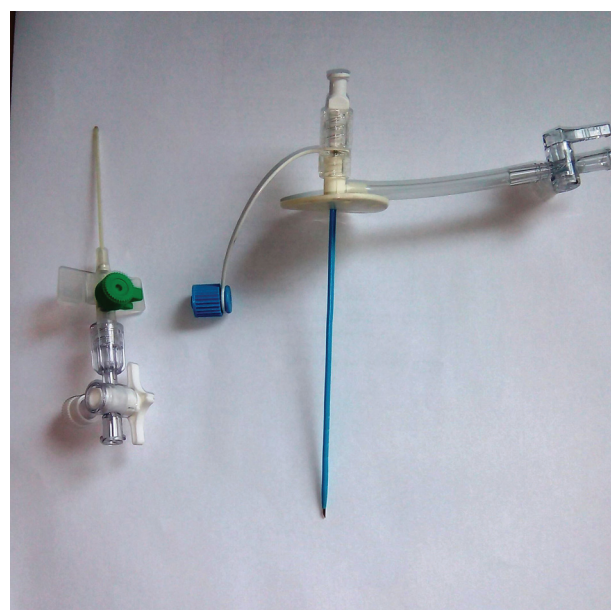
More recently, RCTs have expanded the scope of experimenting CASP in patients presenting with traumatic pneumothorax [17] or SSP [19]. Thelle *et al.* [19] randomized 127 patients presenting with SP (including 48 patients with SSP) to either needle aspiration or chest drainage and proved for the first time that needle aspiration was safe for patient with SSP, who, additionally, had better immediate success rates for this procedure when compared with chest drainage (69 vs. 32%) [19]. They also found significantly shorter durations of hospitalization for the needle aspiration group; a finding corroborated by the previous series and RCTs. There was no significant difference in recurrence at 1-year using either modality [20]. Another benefit cited in most

of these studies (and a point not difficult to understand) is that needle aspiration was associated with significantly less discomfort/pain [4]. Needle aspiration is also associated with less anxiety, and limited scar formation unlike chest tubes [21]. Available evidence has also shown that, with increased use of aspiration, PSP can be treated more frequently as an emergency department-based disease instead of an in-hospital disease, with positive effects on the costs of medical care [21].

The technique

After confirmation of the presence of pneumothorax, a diagnosis was usually made with the aid of an erect chest radiography; the decision to drain is usually taken depending on how dyspneic the patient is. The procedure side is marked and then the skin at the front of the chest is properly cleansed. The optimal site for aspiration is the second intercostal space at the midclavicular line. Local anesthesia usually suffices as long as the skin and the parietal pleura are generously anesthetized. Final confirmation of the presence of pneumothorax is achieved when the needle injecting the local anesthetic is able to aspirate air. In many institutes, a specific kit is available for pleural aspiration and is composed of a catheter over needle attached to a syringe with a stopcock (Fig. 1). An 18 G intravenous cannula attached to a three-way stopcock is more than sufficient for the job if the special kit is not available (Fig. 1). Regardless of the instrument used, the technique is the same. After proper anesthesia, the

Figure 1



Specialized catheter for pleural aspiration (right) and an 18 G cannula attached to three-way stopcock.

catheter is introduced with needle inside it. Once air is aspirated, the catheter/cannula is advanced over the needle till its end and then the needle is withdrawn to avoid injury to the underlying lung. Manual aspiration follows by the means of a syringe draining to a bag. Meticulous calculation of the volume of aspirated air is necessary. The process is continued until no air is aspirated or the patient feels chest pain. A chest radiography should be done very shortly afterward. If the residual pneumothorax in the new radiography is small and patients experience improvement in dyspnea, they can be discharged. If air is continuously aspirated beyond 2.5 l (a sign of ongoing air leak), the procedure should be considered unsuccessful and a chest tube should be inserted. Also if the follow-up radiography does not show resolution of pneumothorax, chest tube insertion rather than a second trial of aspiration is warranted. Figure 2 shows a case of PSP successfully managed by needle aspiration at the Chest Diseases Department in Alexandria University. Overall, 1100 ml of air was aspirated in this case, and immediate postprocedure

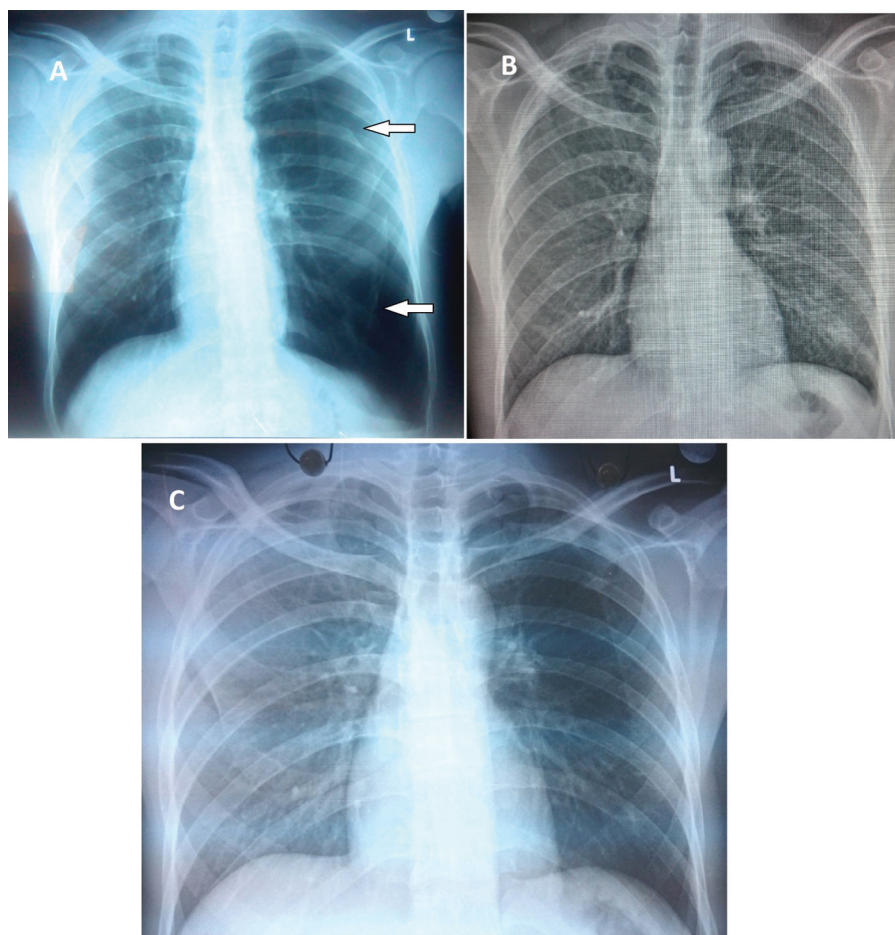
radiography shows near total resolution of the pneumothorax (Fig. 2b).

Ambulatory management

The evidence

The attachment of a one-way valve to a chest tube in the emergency department as well as the subsequent discharge from hospital has been proved as a feasible and safe option for patients with different types of pneumothorax since the 1970s [14]. In a pilot study in 2006, Marquette *et al.* [22] inserted an 8-F pigtail catheter attached to a Heimlich valve in 41 patients presenting with the first episode of PSP. Patients who did not show good re-expansion after 2 h had their tubes attached to suction. If expansion occurred (with or without suction), patients were discharged and had a follow-up appointment every other day. Patients who continued to have air leak at 4 days were referred for thoracoscopy [22]. The 1-week success rate was reported in 85% of study patients [22]. The same group later repeated the study on 60 patients with PSP and reported a very similar 1-week success rate

Figure 2



(a) Chest radiography at presentation showing left pneumothorax and collapsed lung (arrows). (b) Immediate postaspiration radiography showing only a small apical cap of pneumothorax. (c) Chest radiography done 4 weeks after procedure confirms nonrecurrence.

of 83% [23]. Further studies using different variations of the Heimlich valve that recruited patients with PSP as well as SSP and iatrogenic pneumothorax reported success rates of 73–78% [24,25]. Ho *et al.* [26] randomized 48 patients with PSP to either needle aspiration or chest drain with one-way valve and found very similar success rates. A systematic review of studies on ambulatory management of pneumothorax using a Heimlich valve type found a pooled success rate of outpatient management of patients with different types of pneumothorax to be between 75 and 80% [14]. None of the studies reviewed reported any fatality or serious complication like lung/visceral pleural laceration [14]. The main criticism for the reported studies in the review was the lack of RCTs that directly compare this modality to the standard technique of chest tube with underwater seal [14]. To address this research need, there are currently two large multicentre UK RCTs comparing ambulatory management of pneumothorax to traditional chest tube in patients with PSP (ISRCTN 79151659) and SSP (ISRCTN 79956557).

The technique

All studies reporting the use of ambulatory management use either small-bore chest drains (8–12 F) inserted with Seldinger technique (Fig. 3) or specialized CASP kits (Fig. 1). Larger chest drains (>16 F) are rarely needed, as there is evidence of the equivalent efficacy with smaller sized drains, with the advantage of the latter of causing less pain and smaller scars [27]. The insertion site is usually either the second intercostal space at the midclavicular line or at the triangle of safety (midaxillary line above the sixth rib). The earlier site is preferred by some because the catheter and the attached device would not interfere

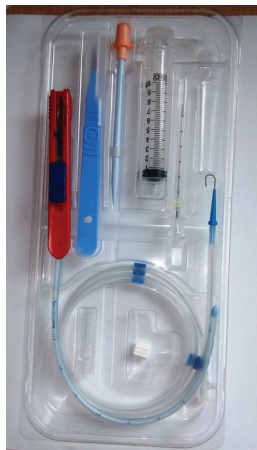with arm movements during walking or if the patient wants to sleep on that side. After confirmation of successful insertion, the catheter/drain is attached to a one-way valve of the many types commercially available (Fig. 4). The different types of valves come with fitting tubes to allow attachment to either conventional chest tubes or smaller catheters. A postprocedure radiography is done to confirm re-expansion of the lung. Most centers do not prefer to remove the catheter at this stage but rather to discharge the patient and follow them up in 24–48 h and then either daily or every other day until a week has elapsed. The tube is removed at any point during the follow-up if a chest radiography is showing near-complete expansion and no air is coming from the valve. Persistent air leak or failure of re-expansion should prompt surgical referral.

Guidelines and everyday practice

The most widely cited management guidelines for pneumothorax are the American College of Chest Physicians statement issued in 2001 [5] and the BTS guidelines published in 2010 [3]. The uptake of these relatively new ‘outpatient’ management strategies varies between the two societies mainly because of the availability of good quality evidence when each document was prepared.

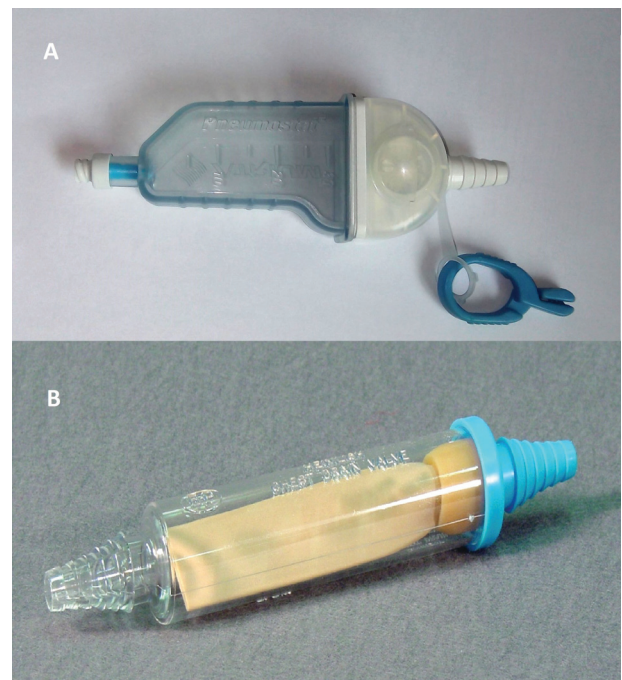
Although the American College of Chest Physicians statement does not support needle aspiration for

Figure 3



Special kit for 12-F chest drain for insertion by Seldinger’s technique.

Figure 4



(a) Pneumostat atrium valve; (b) classical Heimlich valve.

managing SP, the BTS guidelines advocate it for any patient with symptomatic large PSP (>2 cm) and for patients with small symptomatic SSP (1–2 cm in depth) [3]. The BTS puts emphasis on the importance of performing the technique by practitioners who are familiar with it and have experience with dealing with pleural diseases. Patients who are too unwell or present with tension or bilateral pneumothoraces should proceed directly to chest tube and hospital admission.

Despite the fact that this scheme is considered the standard of care in many parts of the world, deviation from this practice is widely reported [28]. In Egypt, the chest tube underwater seal is still the standard of care for all patients with SP who need drainage [29].

Given the compelling evidence of the safety of outpatient management of stable patient with SP (both PSP and SSP), the question arises as to why these techniques do not replace the insertion of the ordinary chest drains and the underwater seal as the initial management in patients with SP? It is curious to note that some respiratory centers have established an ambulatory service for pneumothorax, where needle aspiration is first tried (as per BTS guidelines) and if unsuccessful, a chest tube is inserted and attached to a one-way valve thus eliminating the need of hospitalization in a significant portion of their patients [30]. It is worth mentioning that a small but significant subset of patients with SP will need hospitalization and a standard chest tube because of indications cited above. In addition, patients who are too frail or who cannot return to hospital in due course if problems arise should be hospitalized and have the traditional chest drain. However, for the remaining majority, is it safe to say that it is time to depart from the chest tube underwater seal as the title of the review suggests? Widespread application of these techniques can save several hundreds of days of hospitalizations across the country and redirect resources to other crucial respiratory conditions. The current status suggests that this is unlikely to happen in the near future, as it is not easy to change the conviction of clinicians about procedures that are regarded as gold standard. It is hoped from this brief review to plant some seeds of curiosity in the minds of respiratory physicians to explore more about these options and hopefully apply them in the future.

Conclusion

It seems appropriate to conclude that, in the management of SP, 'less is more'. Needle aspiration

is successful in many patients, which made it a recommended practice. Ambulatory management with one-way valves is emerging as a viable option, and results of ongoing RCTs will potentially affect the synthesis of future guidelines. Even in the situation where a chest tube with underwater seal is required, very small drains (8–12 F) are as effective as the larger ones.

Acknowledgements

Maged Hassan is a recipient of European Respiratory Society long-term research fellowship – ERS LTRF 7333.

Financial support and sponsorship

Nil.

Conflicts of interest

There are no conflicts of interest.

References

- 1 Kaya SO, Karatepe M, Tok T, Onem G, Dursunoglu N, Goksin I. Were pneumothorax and its management known in 15th-century anatolia? *Tex Heart Inst J* 2009; **36**:152–153.
- 2 Bintliffe OJ, Hallifax RJ, Edey A, Feller-Kopman D, Lee YCG, Marquette CH, et al. Spontaneous pneumothorax: time to rethink management? *Lancet Respir Med* 2015; **3**:578–588.
- 3 MacDuff A, Arnold A, Harvey J, on behalf of the BTS Pleural Disease Guideline Group. Management of spontaneous pneumothorax: British Thoracic Society pleural disease guideline 2010. *Thorax* 2010; **65**: ii18–ii31.
- 4 Tschopp J-M, Bintliffe O, Astoul P, Canalis E, Driesen P, Janssen J, et al. ERS task force statement: diagnosis and treatment of primary spontaneous pneumothorax. *Eur Respir J* 2015; **46**:321–335.
- 5 Baumann MH, Strange C, Heffner JE, Light R, Kirby TJ, Klein J, et al. Management of spontaneous pneumothorax: an American College of Chest Physicians Delphi consensus statement. *Chest* 2001; **119**:590–602.
- 6 Kelly A-M, Loy J, Tsang AYL, Graham CA. Estimating the rate of re-expansion of spontaneous pneumothorax by a formula derived from computed tomography volumetry studies. *Emerg Med J* 2006; **23**: 780–782.
- 7 Hallifax RJ, Yousuf A, Jones HE, Corcoran JP, Psallidas I, Rahman NM. Effectiveness of chemical pleurodesis in spontaneous pneumothorax recurrence prevention: a systematic review. *Thorax* 2016; Online First: 01 November 2016. doi: 10.1136/thoraxjnl-2015-207967.
- 8 Hamilton AA, Archer GJ. Treatment of pneumothorax by simple aspiration. *Thorax* 1983; **38**:934–936.
- 9 Klassen KP, Meckstroth CV. Treatment of spontaneous pneumothorax: prompt expansion with controlled thoracotomy tube suction. *JAMA* 1962; **182**:1–5.
- 10 Ruckley CV, McCormack RJ. The management of spontaneous pneumothorax. *Thorax* 1966; **21**:139–144.
- 11 Obeid FN, Shapiro MJ, Richardson HH, Horst HM, Bivins BA. Catheter aspiration for simple pneumothorax (CASP) in the outpatient management of simple traumatic pneumothorax. *J Trauma* 1985; **25**:882–886.
- 12 Vallee P, Sullivan M, Richardson H, Bivins B, Tomlanovich M. Sequential treatment of a simple pneumothorax. *Ann Emerg Med*. 1988; **17**: 936–942.
- 13 Bernstein A, Waqaruddin M, Shah M. Management of spontaneous pneumothorax using a Heimlich flutter valve. *Thorax* 1973; **28**:386–389.
- 14 Brims FJH, Maskell NA. Ambulatory treatment in the management of pneumothorax: a systematic review of the literature. *Thorax* 2013; **68**:664–669.

- 15 Ayed AK, Chandrasekaran C, Sukumar M. Aspiration versus tube drainage in primary spontaneous pneumothorax: a randomised study. *Eur Respir J*. 2006; **27**:477–482.
- 16 Noppen M, Alexander P, Driesen P, Slabbynck H, Verstraeten A. Manual aspiration versus chest tube drainage in first episodes of primary spontaneous pneumothorax: a multicenter, prospective, randomized pilot study. *Am J Respir Crit Care Med* 2002; **165**:1240–1244.
- 17 Parlak M, Uil SM, van den Berg JWK. A prospective, randomised trial of pneumothorax therapy: manual aspiration versus conventional chest tube drainage. *Respir Med* 2012; **106**:1600–1605.
- 18 Wakai A, O'Sullivan RG, McCabe G. Simple aspiration versus intercostal tube drainage for primary spontaneous pneumothorax in adults. *Cochrane Database Syst Rev* 2007; **24**:CD004479.
- 19 Thelle A, Gjerdevik M, SueChu M, Hagen OM, Bakke P. Randomised comparison of needle aspiration and chest tube drainage in spontaneous pneumothorax. *Eur Respir J* 2017; **49**:1601296.
- 20 Devanand A, Koh MS, Ong TH, Low SY, Phua GC, Tan KL, *et al*. Simple aspiration versus chest-tube insertion in the management of primary spontaneous pneumothorax: a systematic review. *Respir Med* 2004; **98**:579–590.
- 21 Janssen J, Cardillo G. Primary spontaneous pneumothorax: towards outpatient treatment and abandoning chest tube drainage. *Respiration* 2011; **82**:201–203.
- 22 Marquette C-H., Marx A, Leroy S, Vaniet F, Ramon P, Caussade S, *et al*. Simplified stepwise management of primary spontaneous pneumothorax: a pilot study. *Eur Respir J*. 2006; **27**:470–476.
- 23 Massongo M, Leroy S, Scherpereel A, Vaniet F, Dhalluin X, Chahine B, *et al*. Outpatient management of primary spontaneous pneumothorax: a prospective study. *Eur Respir J* 2014; **43**: 582–590.
- 24 Voisin F, Sohler L, Rochas Y, Kerjouan M, Ricordel C, Belleguic C, *et al*. Ambulatory management of large spontaneous pneumothorax? With pigtail catheters. *Ann Emerg Med* 2014; **64**:222–228.
- 25 Woo WG, Joo S, Lee GD, Haam SJ, Lee S. Outpatient treatment for pneumothorax using a portable small-bore chest tube: a clinical report. *Korean J Thorac Cardiovasc Surg* 2016; **49**:185–189.
- 26 Ho KK, Ong MEH, Koh MS, Wong E, Raghuram J. A randomized controlled trial comparing minichest tube and needle aspiration in outpatient management of primary spontaneous pneumothorax. *Am J Emerg Med* 2011; **29**:1152–1157.
- 27 Baumann MH, Patel PB, Roney CW, Petrini MF. Comparison of function of commercially available pleural drainage units and catheters. *Chest* 2003; **123**:1878–1886.
- 28 Kelly A-M, Clooney M, Spontaneous Pneumothorax Australia Study Group. Deviation from published guidelines in the management of primary spontaneous pneumothorax in Australia. *Intern Med J* 2008; **38**:64–67.
- 29 Korraa E, Madkour A, Shoukri A, Ahmed S. Outcome of patients with spontaneous pneumothorax admitted in Abbasia Chest Hospital. *Egypt J Bronchol* 2016; **10**:355.
- 30 Thomas K, Naeem M, Reddy R. P173 ambulatory management of spontaneous pneumothorax. *Thorax* 2014; **69**:A150–A151.