

Respiratory failure in a patient with treated thymoma: A blast from the past

Animesh Ray^a, Vivek Nangia^b, Rajat Chatterji^c, Nikhil Bante^d

Thymomas are among the most common anterior mediastinal tumors that can uncommonly present with respiratory failure. This case discusses the development of type II respiratory failure in a patient with a history of treated and cured thymoma. The problem posed and the workup leading to the diagnosis is discussed in detail. Further, the possible and reported causes of respiratory failure in such a case has also been highlighted.

Egypt J Bronchol 2017 11:168–170

© 2017 Egyptian Journal of Bronchology

Egyptian Journal of Bronchology 2017 11:168–170

Introduction

Thymomas are one of the most common anterior mediastinal tumors with various symptoms indicating compression of the mediastinal structures. The characteristics of the tumor vary depending on the degree of neoplasia and can show metastasis in distant organs. Respiratory failure associated with thymoma is less commonly described, which can be ascribed to a number of causes. This case report sheds light on the course of respiratory failure in a patient with malignant thymoma with metastasis.

Case report

A 52-year-old man, a known case of malignant thymoma Masaoka stage I, presented with complaints of gradually progressing shortness of breath since 2 months. The shortness of breath was initially exertional, which gradually progressed to that at rest. It was not associated with wheezing. There was no diurnal variation and it significantly increased in the recumbent position. There was no history of cough, chest pain, hemoptysis, or other symptoms pertaining to other systems. He had undergone a subtotal colectomy 3 years ago for acute megacolon. He had undergone thymectomy 4 years back with postoperative radiotherapy and had been declared cured of the disease. Systemic examination, including cardiological and neurological workup, was normal. Arterial blood gases showed type 2 respiratory failure.

Noninvasive ventilation was initiated along with nebulization with B2 agonists and antimuscarinics. Initial workup including routine blood investigations and echocardiography were normal. Chest radiograph was done, which showed elevated left cupola of the diaphragm, which had developed after thymectomy (likely an injury to the phrenic nerve) and had been

Keywords: metastasis, myasthenia gravis, respiratory failure, thymoma

^aAssistant Professor, Department of Medicine, AIIMS (New Delhi), ^bHOD & Senior Consultant, Department of Pulmonary Critical Care & Sleep Medicine, Fortis Hospital, Vasant Kunj, New Delhi, ^cSenior Consultant, Department of Pulmonary Critical Care & Sleep Medicine, Fortis Hospital, Vasant Kunj, New Delhi, ^dFNB Fellow, Critical Care Medicine, Indraprastha Apollo Hospitals, New Delhi

Correspondence to Animesh Ray, 290 Parnasree, - 700 060 Kolkata, India
e-mail: doctoranimeshray@gmail.com

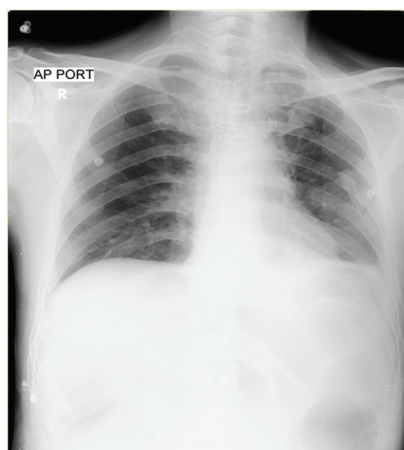
Received 8 February 2017 **Accepted** 8 February 2017

stable since the last 4 years (Fig. 1). A computed tomography (CT) of the thorax showed few parenchymal bands in the left upper lobe and a few pleural nodules in the left upper and lower lobe (possibly radiation induced), with no evidence of recurrence of the thymic malignancy. The antiacetylcholine receptor antibody titer was very high and antistriated muscle antibody was also positive. Subsequently, a repetitive nerve stimulation test of the limbs was done, which was negative. A Tensilon test showed partial improvement in the symptoms as well as in forced vital capacity. A diagnosis of myasthenia gravis with myasthenic crisis was made tentatively, and treatment with anticholinesterases was started. Intravenous immunoglobulin was added with steroids in high doses. The patient showed improvement with this therapy and his symptoms decreased. The intensity and duration of Non-invasive ventilation (NIV) support also decreased. However, he continued to be in respiratory failure.

Antiacetylcholine receptor antibody has a very high sensitivity and specificity for the diagnosis of myasthenia gravis. In less than 5% of cases the result may be false positive, as in motor neuron disease, polymyositis, primary biliary cholangitis, systemic lupus erythematosus, thymoma without myasthenia gravis, etc. [1]. Investigations like repetitive nerve stimulation test have a much lower sensitivity and specificity, which are much lower if the investigations are performed in cases without generalized myasthenia gravis (as in our case) [2].

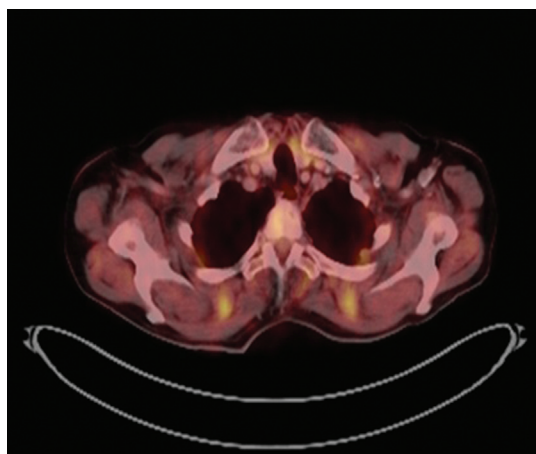
This is an open access article distributed under the terms of the Creative Commons Attribution-NonCommercial-ShareAlike 3.0 License, which allows others to remix, tweak, and build upon the work noncommercially, as long as the author is credited and the new creations are licensed under the identical terms.

Figure 1



CXR showing elevated left cupola of diaphragm which was present since patient underwent thymectomy 4 years back.

Figure 2



FDG PET showing mild FDG avidity in the pleural nodules present in the left lung.

Even in cases of thymoma, which may itself be associated with antiacetylcholine receptor antibody, a rising titer after thymectomy (present in our case) is a definite risk factor for myasthenia gravis. The most probable diagnosis seemed myasthenia gravis, but the partial response to therapy and the late presentation led us to suspect whether there was a recurrence of thymoma. A PET CT scan was performed, which revealed mild ^{18}F -FDG avidity in the pleural nodules with no evidence of abnormal uptake in the mediastinum or elsewhere (Fig. 2). A CT-guided tru-cut biopsy was performed, which showed metastases from thymoma, Masaoka stage IVa. In consultation with the oncologist it was decided to address the pleural metastasis, which was the likely source of antiacetylcholinesterase antibody. The patient was started on palliative chemotherapy (carboplatin and paclitaxel). However, he shortly

Table 1 List of causes of respiratory failure described in patients with thymoma

Causes of respiratory failure
Myasthenia gravis
Phrenic nerve injury
Diffuse panbronchiolitis
Polymyositis

developed healthcare-associated pneumonia with sepsis and septic shock and died. The family did not agree to a post-mortem examination.

Discussion

Thymomas are a type of thymic neoplasms arising in the anterior mediastinum. In the backdrop of thymoma, respiratory failure has been declared in a handful of special causes (Table 1).

Thymoma can be associated with a number of paraneoplastic syndromes, most notably myasthenia gravis. Up to one-half of patients with thymoma have symptoms consistent with myasthenia gravis [3]. Although myasthenia gravis can present with generalized weakness progressing to respiratory failure, instances of isolated respiratory failure due to myasthenia gravis has also been reported [4]. Thymectomy seems to have a role in decreasing the frequency and severity of myasthenia gravis in thymoma patients [5]. Thymectomy is rarely associated with phrenic nerve damage resulting in diaphragmatic weakness leading to respiratory failure. Although the incidence of phrenic nerve damage is less when compared with other intrathoracic interventions, the prognosis in such cases seems to be worse [6,7]. Polymyositis is an inflammatory condition of the muscle resulting in symmetrical and predominantly proximal muscle involvement characterized by raised creatine kinase enzymes, electromyographic changes of myopathy, as well as diagnostic histopathological features. Rini and Gajewski [8] had reviewed the literature and reported 22 cases of polymyositis in association with thymoma. Diffuse panbronchiolitis is a disease of unknown etiology reported predominantly in Japanese individuals and is characterized by symptoms of chronic sinusitis, cough, wheeze, dyspnea, and weight loss. Radiologically there can be diffuse centrilobular nodules and linear opacities corresponding to thickened and dilated bronchiolar walls with intraluminal mucus plugs. It also shows characteristic histopathological changes. Xie *et al.* [9] had reviewed two cases of diffuse panbronchiolitis complicated by thymoma leading to respiratory

failure. It is not clear whether the causation and evolution of the two diseases are related.

This case brings to the fore several issues. This case depicted a case of respiratory failure most likely due to myasthenia gravis that developed in a patient with recurrent thymoma with pleural metastases. Although pleural metastases due to thymic neoplasm leading to refractory myasthenia gravis have been reported [10], to the best of our knowledge this represents the first case of recurrent thymoma with pleural metastases presenting as respiratory failure likely due to myasthenia gravis. The challenges in the diagnosis of the cause of respiratory failure in a case of thymoma forms the crux of the case and the therapeutic implications are also noteworthy. Finally, the presentation of myasthenia gravis without generalized weakness itself is a rare manifestation, being reported in only a handful of cases.

Financial support and sponsorship

Nil.

Conflicts of interest

There are no conflicts of interest.

References

- 1 Pascuzzi RM, Phillips LH II, Johns TR, Lennon VA. The prevalence of electrophysiological and immunological abnormalities in asymptomatic relatives of patients with myasthenia gravis. *Ann N Y Acad Sci* 1987; **505**:407–415.
- 2 Younger DS, Worrall BB, Penn AS. Myasthenia gravis: historical perspective and overview. *Neurology* 1997; **48**:S1–S7.
- 3 Safieddine N, Liu G, Cuningham K, Ming T, Hwang D, Brade A, et al. Prognostic factors for cure, recurrence and long-term survival after surgical resection of thymoma. *J Thorac Oncol* 2014; **9**: 1018–1022.
- 4 Kim WH, Kim JH, Kim EK, Yun SP, Kim KK, Kim WC, et al. Myasthenia gravis presenting as isolated respiratory failure: a case report. *Korean J Intern Med* 2010; **25**:101–104.
- 5 Soleimani A, Moayyeri A, Akhondzadeh S, Sadatsafavi M, Tavakoli Shalmani H, Soltanzadeh A. Frequency of myasthenic crisis in relation to thymectomy in generalized myasthenia gravis: a 17-year experience. *BMC Neurol* 2004; **4**:12.
- 6 Zuera R, Casas JI, Tarradell R, Fernández JA, Villar JM. Acute respiratory insufficiency following thymectomy: an unusual cause [in Spanish]. *Rev Esp Anestesiol Reanim* 1989; **36**:51–53.
- 7 Ostrowska M, de Carvalho M. Prognosis of phrenic nerve injury following thoracic interventions: four new cases and a review. *Clin Neurol Neurosurg* 2012; **114**:199–204.
- 8 Rini BI, Gajewski TF. Polymyositis with respiratory muscle weakness requiring mechanical ventilation in a patient with metastatic thymoma treated with octreotide. *Ann Oncol* 1999; **10**:973–979.
- 9 Xie G, Li L, Liu H, Xu K, Zhu Y. Diffuse panbronchiolitis complicated with thymoma: a report of 2 cases with literature review. *Chin Med J (Engl)* 2003; **116**:1723–1727.
- 10 Colaco C, Colaco B, Mittadodla PS, Badireddi S. Respiratory failure in a patient with metastatic thymoma and myasthenia gravis: a therapeutic challenge. *Am J Respir Crit Care Med* 2014; **189**:A2928.