

# Pericardial cyst masquerading as lung carcinoma

Viswesvaran Balasubramanian, Shibdas Chakrabarti, Nitesh Gupta, Abhijeet Singh

Pericardial cyst is a benign congenital malformation, with uncommon incidence of approximately 1 in 100 000. It accounts for 7% of all mediastinal masses and is rarely associated with complications. Prompt discrimination of this benign lesion from metastasis in a patient with malignancy is of paramount significance in deciding exact line of management. Here, we report a case of pericardial cyst masquerading as a metastatic lung carcinoma in a patient previously treated for breast carcinoma.

*Egypt J Bronchol* 2018 12:370–372

© 2018 Egyptian Journal of Bronchology

## Introduction

Pericardial cysts are benign congenital malformations due to failure of fusion of one of the mesenchymal lacunae that form the pericardial sac [1]. It is uncommon with a reported incidence of approximately 1 in 100 000 and accounts for ~7% of all mediastinal masses and 33% of mediastinal cysts [2,3]. Pericardial cysts evoke much interest as they manifest with diverse anatomical and clinical presentations. They usually remain asymptomatic and are detected incidentally on chest radiography. However, they can be symptomatic and are associated with complications like compression of main stem bronchus and cardiac tamponade due to spontaneous hemorrhage into the cyst [4,5]. The atypical presentations could create diagnostic as well as therapeutic challenges for clinicians. Here, we report a case of pericardial cyst masquerading as metastatic lung carcinoma in a patient previously treated for breast carcinoma.

## Case report

A 44-year-old postmenopausal woman with history of modified radical mastectomy and postoperative chemotherapy for invasive ductal carcinoma of left breast 3 years back presented to pulmonology outpatient department for routine preanesthetic evaluation for orthopedic surgery (left knee replacement for osteoarthritis). Patient denied any history of breathlessness, cough, chest pain, hemoptysis, fever, or loss of weight or appetite. There was no history of exposure to tuberculosis, joint pains, or rash. On examination, the patient was afebrile with SpO<sub>2</sub> of 98% on room air, pulse rate of 78/min, respiratory rate of 15/min, and blood pressure of 120/80 mmHg, and auscultation of chest revealed decreased breath

*Egyptian Journal of Bronchology* 2018 12:370–372

**Keywords:** carcinoma breast, chest radiography, lung cancer, pericardial cyst

Department of Pulmonary, Critical Care and Sleep Medicine, VMMC and Safdarjung Hospital, New Delhi, India

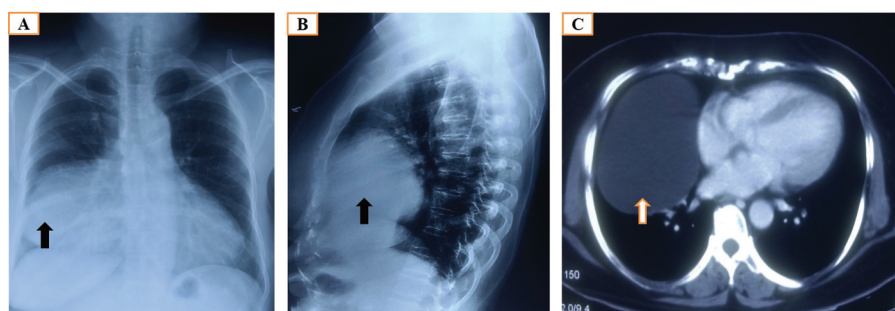
Correspondence to Abhijeet Singh, MD, Department of Pulmonary, Critical Care and Sleep Medicine, VMMC and Safdarjung Hospital, New Delhi 110029, India. Tel: (+91) 8860872269; fax: 011-26163072; e-mail: appu.abhijeet@gmail.com

**Received** 4 December 2017 **Accepted** 30 January 2018

sounds in right infra-mammary and infra-axillary region. Chest radiography showed a homogenous opacity in the right middle and lower zone with loss of cardiac silhouette (Fig. 1a). Lateral chest radiography showed homogenous opacity in anterior and middle mediastinum (Fig. 1b). Contrast-enhanced computed tomography (CT) of the thorax showed a well-defined cystic lesion with smooth margins measuring 10×8×7 cm adjacent to the pericardium on the right side obliterating the right cardiophrenic sulcus and abutting the right diaphragm with no signs of infiltration suggestive of pericardial cyst (Fig. 1c). Contrast-enhanced CT result of the abdomen was normal. PET showed absence of <sup>18</sup>F-fluorodeoxyglucose avid uptake in the cystic lesion and also other sites with no evidence of any metastasis. Bronchoscopy was performed, and findings were unremarkable. Echocardiography done confirmed the presence of cystic mass arising from pericardium with normal chamber dimensions and ejection fraction without evidence of valvular abnormalities or pericardial effusion. Ultrasound of the abdomen revealed grade 1 fatty liver. Extensive investigations like sputum for acid-fast bacilli, blood cultures, mantoux test, collagen vascular disease markers, and serology for echinococcosis were negative. CT-guided transthoracic fine needle aspiration cytology and biopsy of lesion revealed fibrocollagenous lining of cystic wall with aspiration of brownish fluid and no evidence of epithelial elements, lamellated membrane of hydatid disease, granulomas, and atypical cells. A diagnosis of giant asymptomatic pericardial cyst was made based on investigations and patient was kept under

This is an open access journal, and articles are distributed under the terms of the Creative Commons Attribution-NonCommercial-ShareAlike 4.0 License, which allows others to remix, tweak, and build upon the work non-commercially, as long as appropriate credit is given and the new creations are licensed under the identical terms.

Figure 1



(a) Chest radiography postero-anterior view (PA) view showing a lobulated well-defined homogenous mass lesion in the right mid and lower zone with loss of breast tissue shadow on left side (indicated by black arrow); (b) chest radiography lateral view showing a lobulated well-defined homogenous mass lesion adjacent to the heart in the anterior and middle mediastinum (indicated by black arrow); (c) contrast-enhanced computed tomography of the chest showing a lobulated well-defined homogenous cystic lesion adjacent to the heart on right side (indicated by white arrow).

observation with serial monitoring by transthoracic echocardiography. Thoracic surgery consultation was not taken as the patient denied any respiratory complaints. A retrospective evaluation regarding the existence of cystic mass could not be done as the patient was unaware and also lost previous records. The diagnosis can be misleading as any clinician will initially suspect such lesion on chest radiography to be of metastatic malignant etiology considering the background history of this case.

## Discussion

Pericardial cysts are usually benign congenital lesions but can be acquired owing to infections, trauma, after cardiac surgery, and chronic hemodialysis. Majority are asymptomatic (50–75%). However, they can manifest with varying symptoms such as recurrent chest pain, breathlessness, cough, dysphagia, and a feeling of retrosternal pressure owing to compression of nearby structures [6,7]. They can also lead to rare complications like cardiac compression, right ventricular outflow tract obstruction, rupture and tamponade, cyst infection, pneumothorax, atrial fibrillation, or even sudden death [7,8]. Most cases are diagnosed incidentally during routine chest radiography or echocardiography. However, confirmation requires further testing, and contrast-enhanced CT scan is the modality of choice for diagnosis and follow-up [7–9]. Other diagnostic modalities include transthoracic echocardiography and MRI. The existence of right middle and lower zone homogenous opacity as observed in the chest radiograph of present case previously treated for breast cancer resulted in a diagnostic dilemma, and it was imperative to rule out mediastinal metastasis. Contrast-enhanced CT of the chest confirmed the presence of cystic lesion adjacent to the pericardium consistent with pericardial cyst. This was supported by

absence of  $^{18}\text{F}$ -fluorodeoxyglucose-avid lesions on PET scan. Differential diagnoses of pericardial cyst like pericardial fat pad, teratoma, lymphangioma, bronchial and other congenital cysts, localized pericardial effusion, and Morgagni hernia should also be kept in mind as all of them share radiological similarity and may require further evaluation by histopathological evaluation [9]. CT-guided biopsy ruled out any evidence of malignancy in our case. Management of pericardial cysts are dictated by the symptoms. Asymptomatic cysts may be monitored serially by transthoracic echocardiography. Surgical resection by video-assisted thoracoscopy or aspiration may be considered for patients who are symptomatic or with progressive increase in cyst size [7,8]. However, aspiration is associated with recurrence in one-third of cases and can be reduced by sclerosis. The current case was found to be asymptomatic at presentation and kept under observation. Serial transthoracic echocardiographic finding was not suggestive of progression of cyst. Therefore, patient was not offered surgical resection or therapeutic aspiration and was kept under regular follow-up.

## Financial support and sponsorship

Nil.

## Conflicts of interest

There are no conflicts of interest.

## References

- Elamin WF, Hannan K. Pericardial cyst: an unusual cause of pneumonia. *Cases J* 2008; 1:26.
- Patel J, Park C, Michaels J, Rosen S, Kort S. Pericardial cyst: case reports and a literature review. *Echocardiography* 2004; 21:269–272.
- Davis RD, Oldham HN, Sabiston DC. Primary cysts and neoplasms of the mediastinum: recent changes in clinical presentation, methods of diagnosis, management, and results. *Ann Thorac Surg* 1987; 44: 229–237.

- 4 Davis WC, German JD, Johnson NJ. Pericardial diverticulum causing pulmonary obstruction. *Arch Surg* 1961; **82**:285–289.
- 5 King JF, Crosby I, Pugh D, Reed W. Rupture of pericardial cyst. *Chest* 1971; **60**:611–612.
- 6 Sokouti M, Halimi M, Golzari SE. Pericardial cyst presented as chronic cough: a rare case report. *Tanaffos* 2012; **11**:60–62.
- 7 Najib MQ, Chaliki HP, Raizada A, Ganji JL, Panse PM, Click RL. Symptomatic pericardial cyst: a case series. *Eur J Echocardiogr* 2011; **12**:E43.
- 8 Kar SK, Ganguly T. Current concepts of diagnosis and management of pericardial cysts. *Indian Heart J* 2017; **69**:364–370.
- 9 Jeung Mi-Y, Gasser B, Gangi A, Bogorin A, Charneau D, Wihlm JM, *et al*. Imaging of cystic masses of the mediastinum. *RadioGraphics* 2002; **22**:S79–S93.