

Electrocautery and cryotherapy in inoperable malignant lung lesions

Reham M. Elkolaly^a, Emad El-Dine A. Korraa^b, Ibrahim S-E. Ibrahim^a

Background Malignant lung lesions have symptoms that differ according to the lesion site, rate of growth, and diagnosis time. Many palliative modalities have been tried to manage patients' complaints and improve their quality of life. Bronchoscopic electrocautery and cryotherapy are two different techniques that are used in this field.

Objective The aim of the paper was to assess the role of cryotherapy and electrocautery as a palliative treatment for inoperable malignant endobronchial lesions.

Patients and methods A total of 30 patients with inoperable malignant lung lesions were randomized into two groups, 15 patients in each. Group A was subjected to bronchoscopic cryotherapy and group B was subjected to bronchoscopic electrocautery. Dyspnea, cough, hemoptysis, spirometric indices, chest radiography, fiberoptic bronchoscopy, and airway patency were recorded before, 1 week after, and 3 weeks after the last session of each procedure.

Results In group A, symptoms and chest radiography showed improvement in 26–40% to a little extent after 1 week, but showed significant improvement after 3 weeks in 67–80%. In group B, symptoms and chest radiography showed improvement after 1 week in 46–73% and then improvement increased to a lesser degree after 3 weeks in 67–87%. In group A, after 3 weeks, airway reopening was complete in 53.33%, partial in 20%, and no success in 26.67%, whereas in group B, complete success was in 66.67%, partial success was in 20%,

and failure was 13.33% (two cases). In group A, 10 (66.67%) patients required 1–4 sessions whereas in group B, only four (26.67%) patients required second session. Complications were few (hemoptysis, arrhythmia, hypoxemia, and bronchospasm), with a higher rate in group B.

Conclusion Electrocautery and cryotherapy are two different maneuvers for palliative management of endobronchial lesions but with nearly equal outcome on long term. Cryotherapy is safe but requires prolonged time and more than one session are usually required to get satisfactory response, whereas electrocautery is rapid and effective but with few complications.

Egypt J Bronchol 2017 11:74–80

© 2017 Egyptian Journal of Bronchology

Egyptian Journal of Bronchology 2017 11:74–80

Keywords: bronchoscope, cryotherapy, electrocautery, malignancy

^aDepartment of Chest Diseases, Faculty of Medicine, Tanta University, Tanta, ^bDepartment of Chest Diseases, Faculty of Medicine, Ain-Shams University, Cairo, Egypt

Correspondence to Reham Mohammed Elkolaly, PhD, Department of Chest Diseases, Faculty of Medicine, Tanta University Hospitals, Tanta, ElGharbya, 31512, Egypt; Mob: 01227650268; e-mail: r.elkolaly@gmail.com

Received 5 April 2016 **Accepted** 28 February 2017

Introduction

Central airway obstruction is a term used when an endoluminal lesion obstructs the trachea or the main bronchi. Overall, 50% of patients with lung cancer experience airway obstruction [1] owing to endoluminal extension of the tumor, tumor infiltration through the wall, extraluminal compression, or sometimes because of the compressing effect of lymphadenopathy [2].

Many patients with airway malignancy may have different symptoms, for example, hemoptysis, cough, dyspnea, atelectasis, or even obstructive pneumonia [3]. In addition, malignant airway diseases can lead to other clinical manifestations depending on the lesion site, rate of its growth, diagnosis time, and involved tissues and structures [4]. In an attempt to provide relief to inoperable patients, palliative therapy was tried to manage patients' complaints and improve their quality of life. Palliative therapy ranges from radiotherapy, chemotherapy to intervention bronchoscopy, especially in urgent cases [5].

Interventional bronchoscopy has different modalities like lasers, cryotherapy, electrocautery, argon plasma,

photodynamic therapy, and brachytherapy. These techniques vary in availability, safety, expense, ease of use, and effectiveness [6].

Endobronchial electrocautery is considered the fastest maneuver after laser ablation to manage urgent obstructive airway lesions. Electrocautery is now called 'the poor man's laser' [7] owing to its rapid symptom relief because of its thermal role in tumor debulking and fulguration of the endobronchial obstructing tissue using electric current rather than laser light [2].

On the contrary, endobronchial cryotherapy has been used since the 1970s to destroy endobronchial tumors using the effect of ice freezing [8], which is cytotoxic to the malignant tissue, leading to tissue death and sloughing, which later on leads to improvement of symptoms and respiratory function [9].

This is an open access article distributed under the terms of the Creative Commons Attribution-NonCommercial-ShareAlike 3.0 License, which allows others to remix, tweak, and build upon the work noncommercially, as long as the author is credited and the new creations are licensed under the identical terms.

Aim

The aim was to evaluate the outcome of endobronchial electrocautery and endobronchial cryotherapy as two different palliative treatments for patients with inoperable lung cancer.

Patients and methods

The study was previously approved by ethical committee. It was conducted in the chest departments (Bronchoscopy Units) of the Ain-Shams and the Tanta University hospitals during the period from May 2015 to March 2016 on 30 patients. Written consent was obtained from every patient.

Inclusion criteria

The inclusion criteria were diagnosed endobronchial malignant tumor that presents in the main bronchus or lobar bronchi, with identifiable tumor margin, and distressing symptoms related to the airway obstruction such as cough, dyspnea, hemoptysis, or pneumonia.

Exclusion criteria

Operable tumors, uncorrectable hypoxemia, uncorrectable bleeding disorders, severe respiratory distress, and myocardial infarction in the last 6 months were the exclusion criteria.

Patients were enrolled into two groups:

Group A consisted of 15 patients who were managed using cryotherapy.

Group B consisted of 15 patients who were managed using electrocautery.

All patients were subjected to the following:

- (1) Thorough medical history and physical examination (general and local chest), ECG, and arterial blood gas.
- (2) Chest radiography and/or computed tomography scan was done before and 3 weeks after the procedure to assess lung collapse.
- (3) Symptoms were recorded and scored before, 1 week after, and 3 weeks after the last session of each procedure [10]: dyspnea was measured based on American Thoracic Society dyspnea scale (five-point grading system) [11], hemoptysis according to Morice *et al.* [12] (no blood, streaks of blood, clots in 5 days or less in previous 2 weeks, clots in 5 days or more in previous 2 weeks, and blood transfusion), and cough according to Walsh *et al.* [13] (no cough,

cough does not disturb sleep, and cough does disturb sleep).

- (4) Spirometry functions [forced vital capacity (FVC), forced expiratory volume in 1 s (FEV₁), and FEV₁%] before, 1 week after, and 3 weeks after the procedure were recorded.
- (5) Fiberoptic bronchoscopy was done before, 1 week after, and 3 weeks after the procedure.
- (6) Procedure: rigid bronchoscopy was introduced under general anesthesia using intravenous hypnotics (propofol) in an induction dose (1–2 mg/kg) and in a maintenance dose (6–10 mg/kg/h) for analgesia (fentanyl) and neuromuscular relaxation (succinylcholine). During bronchoscopy, ventilation was by bag valve mask, and air/oxygen is delivered through a side port rigid bronchoscope connection. All patients gave their formal consent. The protocol was approved by the ethical committee.
 - (a) Bronchoscopic cryotherapy was done by Erbe Erbokryo Ca (Erbe Elektromedizin GmbH, Tübingen, Germany). Using CO₂ as a cooling agent, the probe was inserted in the tumor, and then repeated cycles of freeze/thaw for 30–40 s each (temperature ~ -60–70°C) were performed. Necrotic tissue was removed by forceps or by suction.
 - (b) Bronchoscopic electrocautery was done using a device (Erbe Elektromedizin GmbH) with high-frequency and unipolar blunt-ended probe that pressed against the tumor base using energy 40–60 W in frequent pulses (till blanching was seen). Inspired oxygen concentrations were kept maximally at 30% if possible. Vaporized tissue was removed mechanically or by suction. The procedure ended when the airway lumen was opened or a maximum of five sessions of electrocautery or cryotherapy were done [14].
- (7) Degree of airways patency was assessed as follow [15]:
 - (a) Complete success: complete ablation of the endobronchial lesion.
 - (b) Partial success: 50% or more of airway lumen was reopened.
 - (c) No success: no decrease in the size of the lesion or less than 50% of lumen reopening.

Statistical analysis

Data was analyzed using statistical package for social sciences, version 15 (SPSS; SPSS Inc., Chicago, Illinois, USA). Student's *t*-test was used to compare mean of the two groups. Comparison between many

groups was done by χ^2 -test. Quantitative data were presented as mean \pm SD.

The threshold for the level of significance is fixed at the 5% level, and a *P* value less than 0.05 considered as significant.

Results

This study was conducted on 30 patients; of which, there were 22 (73.33%) males and eight (26.67%) females. There was no statistically significant difference between the two groups regarding age (Table 1). The tumor site differs in patients of both groups (Table 2).

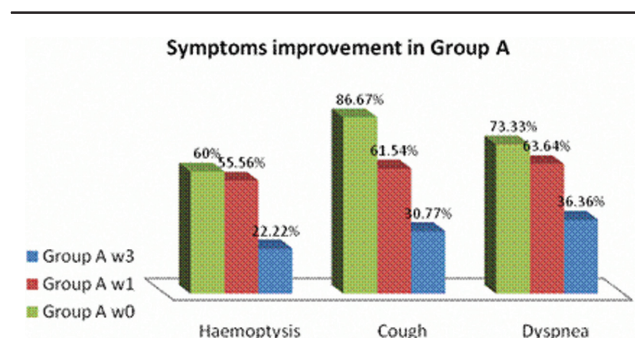
Regarding symptom improvement in group A, dyspnea showed some improvement after 1 week in four (36.36%) of 11 patients, but it gradually improved after 3 weeks in seven (63.64%) of 11 patients by at least 1 to 2 grades. Cough was improved in five (38.46%) of 13 patients after 1 week, but it significantly improved in nine (69.23%) of 13 patients after 3 weeks. Hemoptysis was improved after 1 week in four (44.44%) of nine patients but it significantly improved after three weeks in seven (77.78%) of nine patients (Fig. 1).

In group B, dyspnea was improved after 1 week in five (50%) of 10 patients but after 3 weeks it improved in seven (70%) of 10 patients by at least 1 to 2 grades. Cough after 1 week was improved in nine (64.29%) of 14 patients, and after three weeks, it worsened in

one (7.14%) patient whereas improved in 11 (78.57%) of 14 patients. Hemoptysis was improved in seven (70%) of 10 patients after 1 week and in eight (80%) of 10 patient after 3 weeks (Fig. 2).

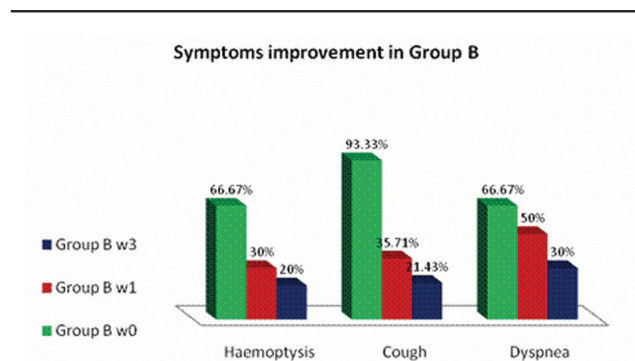
There was no statistically significant difference between the two groups regarding preprocedure FVC; it was 1.62 \pm 0.190 and 1.64 \pm 0.218 in groups A and B, respectively ($t=-0.188$, $P=0.853$), and FEV₁ was 1.32 \pm 0.193 and 1.31 \pm 0.187 in groups A and B, respectively ($t=0.086$, $P=0.932$).

Figure 1



Symptoms improvement in group A (w0=pre procedure, w1=after 1 week and w3=after 3 weeks).

Figure 2



Symptoms improvement in group B (w0=pre procedure, w1=after 1 week and w3=after 3 weeks).

Table 1 Age of patients in both groups

Age (years)	Group A (n=15)	Group B (n=15)	t	P
Range	23–56	38–60	–0.98	0.338
Mean \pm SD	46.33 \pm 8.38	49.2 \pm 7.7		

Table 2 Site of tumor in both groups

	Group A (n=15) [n (%)]	Group B (n=15) [n (%)]	All groups (n=30) [n (%)]
Right main	5 (33.33)	6 (40.0)	11 (36.67)
Right upper	0 (0)	1 (6.67)	1 (3.33)
Right lower	4 (26.67)	1 (6.67)	5 (16.67)
Left main	3 (20.0)	3 (20.0)	6 (20)
Left upper	1 (6.67)	1 (6.67)	2 (6.67)
Left lower	2 (13.33)	3 (20.0)	5 (16.67)
Total	15 (100)	15 (100)	30 (100)

Table 3 Spirometric changes in groups A and B before and after each procedure

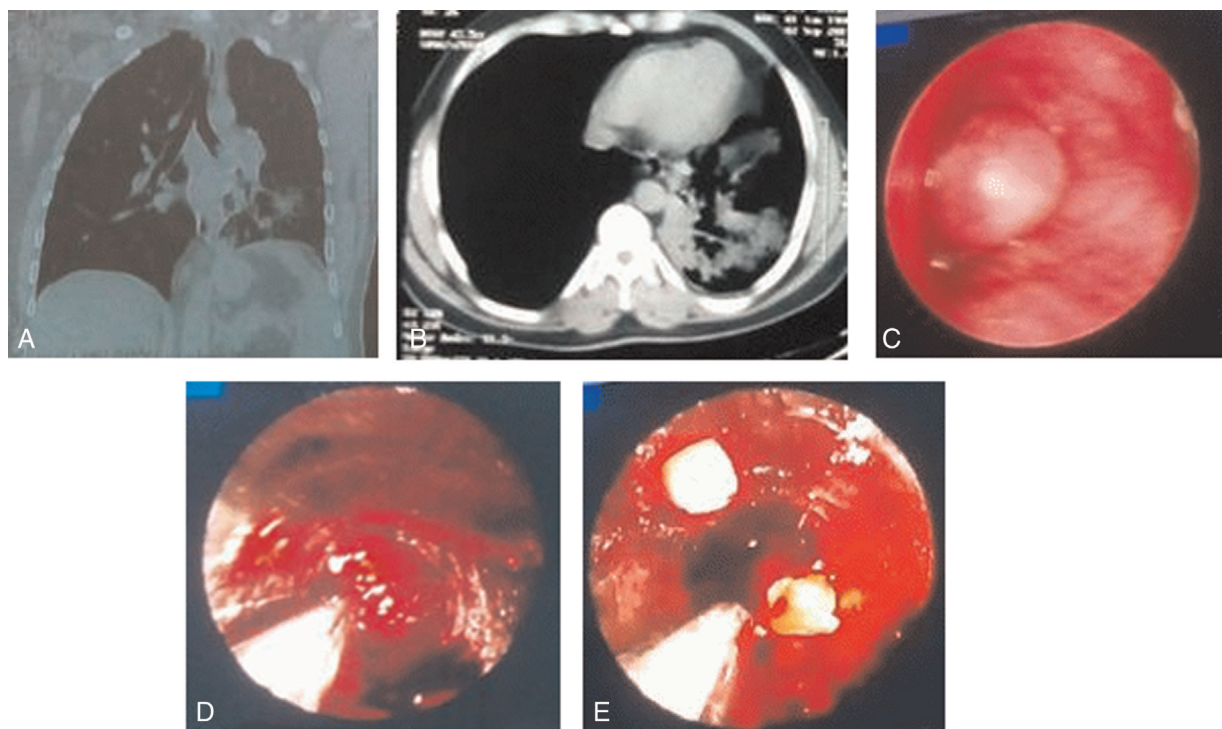
	Group A (mean \pm SD)		Group B (mean \pm SD)	
	FVC	FEV ₁	FVC	FEV ₁
Preprocedure	1.623 \pm 0.190	1.317 \pm 0.193	1.637 \pm 0.218	1.311 \pm 0.187
After 1 week	1.689 \pm 0.134	1.391 \pm 0.141	2.629 \pm 0.449	2.186 \pm 0.421
After 3 weeks	2.685 \pm 0.275	2.348 \pm 0.283	2.773 \pm 0.394	2.367 \pm 0.391
F	123.065	108.392	42.467	39.284
P	<0.001	<0.001	<0.001	<0.001

FEV₁, forced expiratory volume in 1 s; FVC, forced vital capacity.

FVC and FEV₁ were compared before and after each procedure. In group A, there was no significant difference before and 1 week after the procedure, but there was a significant difference between the functions 1 and 3 weeks after the procedure. In group B, there was statically significant difference before and 1 week after the procedure, but there was no significant difference between the functions 1 and 3 weeks after the procedure (Tables 3–5).

Regarding the number of required sessions to achieve more than 50% of airway patency, in group A, 10 (66.67%) patients required more than one session; two (20%) of 10 patients required four sessions, five (50%) of 10 patients required three sessions, and three (30%) of 10 patients required two sessions. In group B, only five (33.33%) patients required two sessions. By the end of the third week, the degree of airway patency differed in each group (Table 6).

Figure 3



(a) Reconstructive coronal CT chest view showing left main obstruction with endobronchial lesion. (b) CT chest mediastinal view showing left lower lobe collapse and necrotic tissue within. (c) Bronchoscopic view of left main bronchus with an obstructing mass. (d) Bronchoscopic view (rigid) during cauterization of the lesion then bronchoscopic coring. (e) Bronchoscopic view after restoration of more than 50% of the airway lumen.

Table 4 Comparison between spirometric changes before, after 1 week, and after 3 weeks in both groups

	FVC in group A			FEV ₁ in group A			FVC in group B			FEV ₁ in group B		
	w0–w1	w1–w3	w0–w3	w0–w1	w1–w3	w0–w3	w0–w1	w1–w3	w0–w3	w0–w1	w1–w3	w0–w3
<i>F</i>	0.870	13.131	14.001	0.947	12.251	13.198	7.390	7.390	8.464	6.869	1.418	8.286
<i>P</i>	0.389	<0.001	<0.001	0.349	<0.001	<0.001	<0.001	0.289	<0.001	<0.001	0.164	<0.001

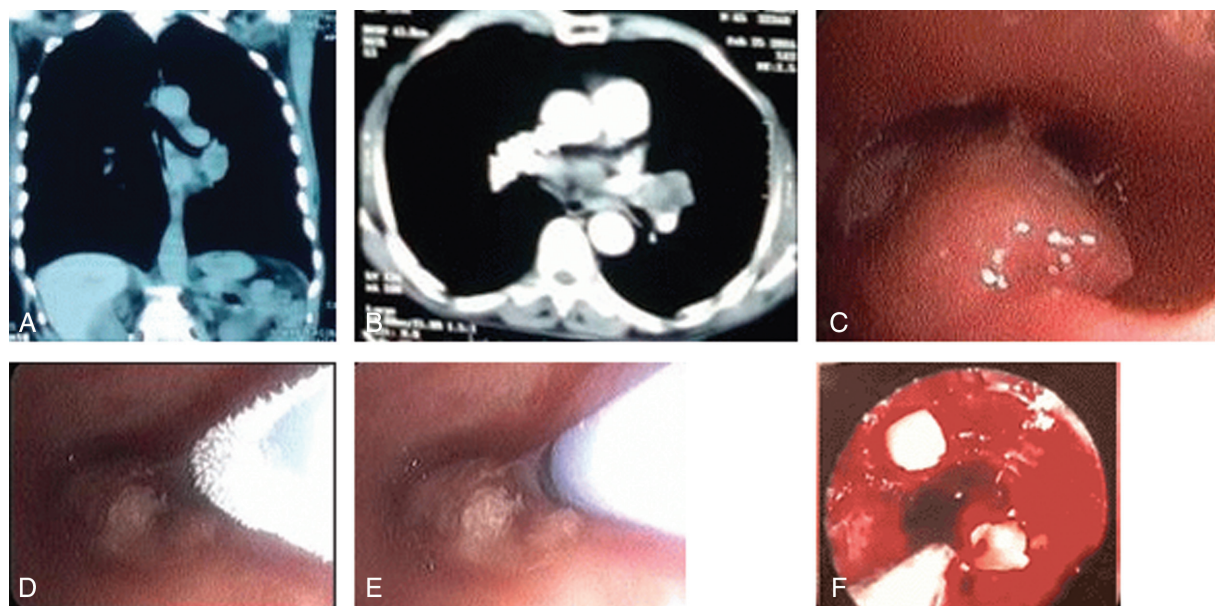
w0, preprocedure; w1, after 1 week; w3, after 3 weeks. FEV₁, forced expiratory volume in 1 s; FVC, forced vital capacity.

Table 5 Comparison of spirometric values in both groups after 1 and 3 weeks

	After 1 week		After 3 weeks	
	FVC	FEV ₁	FVC	FEV ₁
Group A (mean±SD)	1.689±0.134	2.629±0.449	2.685±0.275	2.348±0.283
Group B (mean±SD)	1.391±0.141	2.186±0.421	2.773±0.394	2.367±0.391
<i>t</i>	–7.758	–6.939	–0.704	–0.150
<i>P</i>	<0.001	<0.001	0.487	0.882

FEV₁, forced expiratory volume in 1 s; FVC, forced vital capacity.

Figure 4



(a) Reconstructive coronal CT chest view showing endobronchial lesion in left main bronchus. (b) CT chest; mediastinal view showing mass tissue encasing left main bronchus. (c) Bronchoscopic view of left main bronchus with an obstructing mass. (d) Rigid bronchoscopic view of the mass during cryotherapy (freezing). (e) Rigid bronchoscopic view of the mass during cryotherapy (thawing). (f) Bronchoscopic view after restoration of about 30% of the airway lumen but after 4 sessions of cryotherapy.

Table 6 Degree of airway patency after 3 weeks in each group

	Group A [n (%)]	Group B [n (%)]
Complete success	8 (53.33)	10 (66.67)
Partial success	3 (20)	3 (20)
No response	4 (26.67)	2 (13.33)

Follow-up chest radiology after first week revealed marked improvement in three (20%) cases in group A and insignificant improvement in other cases, but in group B, the improvement was significant in nine (60%) cases. After 3 weeks, follow-up radiology revealed improvement in 10 (66.67%) cases and 12 (80%) cases in groups A and B, respectively; the difference was not significant between the two groups (Figs. 3a–e and 4a–f).

Regarding procedural complications, they were manageable and few in both groups, except in one case in group B, which was complicated by tracheal perforation and managed by stent for 10 days till fistula closure (Table 7).

Discussion

There are more than one bronchoscopic maneuver to deal with endobronchial lesion especially malignant tissues that constitute more than 50% of what is called central airway lesions; these maneuvers are used according to physician's decision to deal with the situation he or she faces, especially life-threatening ones [16].

Table 7 Complications in both groups

	Group A [n (%)]	Group B [n (%)]
Hemoptysis	4 (26.67)	1 (13.33)
Fever	0 (0)	2 (6.67)
Atrial fibrillation	1 (13.33)	0 (0)
Airway perforation	0 (0)	1 (6.67)
Infection	0 (0)	1 (6.67)
Cardiac arrest	0 (0)	0 (0)
Esophagitis	0 (0)	0 (0)

Bronchoscopic electrocautery and cryotherapy are two different applications that are used for hemostasis and debulking of obstructive tissue but with different techniques and in variable effective time.

This study included 30 patients with inoperable malignant airway lesions, and patients were divided into two groups: group A included 15 patients who were subjected to cryotherapy and group B included 15 patients who were subjected to electrocautery.

Symptoms improved in both groups, but they improved significantly more in group B than in group A after the first week: dyspnea improvement was seen in 50% and 36.36% in groups B and A, respectively; cough improvement was seen in 64.29% and 38.46% in groups B and A, respectively; and hemoptysis stopped in 70% and 44.44% of patients in groups B and A, respectively. However, after 3 weeks, both groups were insignificant regarding symptom improvement.

These results were consistent with that of a study conducted by Hosni *et al.* [17], who recorded significant symptom improvement after electrocautery, which was 42.9% for dyspnea, 78.5% for hemoptysis, and 61.5% for cough. Kvale *et al.* [18] also reported rapid and sustained improvement in dyspnea, cough, and bleeding after fiberoptic electrocautery of endobronchial cancer in all studied patients.

Regarding cryotherapy, Maiwand and Asimakopoulos [19] recorded improvement in symptoms of cough in 69% of patients, dyspnea in 59.2%, and hemoptysis in 76.4% after 2 weeks of repeated sessions of cryotherapy. Moreover, Asimakopoulos *et al.* [20] reported that dyspnea improved in 36.6% of patients after two times or more of cryotherapy.

In this study, FVC and FEV₁ were compared before and after in each group and showed insignificant difference in group A after 1 week (1.689±0.134 and 1.391±0.141, respectively) but improved significantly 3 weeks (2.685±0.275 and 2.348±0.283, respectively) after the last session of repeated cryotherapy (2–4 sessions), whereas FVC and FEV₁ showed significant difference in group B after 1 week (2.629±0.449 and 2.186±0.421, respectively) and continued improvement after 3 weeks (2.773±0.394 and 2.367±0.391, respectively).

These results compared with that of Hosni *et al.* [17], who reported an improvement in spirometric pulmonary functions after electrocautery treatment, as FVC increased by 15.8% and FEV₁ by 12.6%. Shehata *et al.* [3] reported improvement in pulmonary functions after endobronchial electrocautery as FVC was 61.82% before electrocautery and then became 69.45% after 1 week and 70.09% after 1 month, whereas FEV₁ was 51.18 before intervention and then 63.91% and 64% after 1 week and 1 month, respectively.

In a study conducted by Asimakopoulos *et al.* [20], no significant improvement in spirometric functions after single session of cryotherapy was reported, but they significantly improved after two sessions or more.

In this study, number of sessions and airway patency varied between the two groups: 66.67% of group A patients required more than two sessions and 53.33% of the patients obtained complete success whereas 20 and 26.67% showed partial and no response,

respectively. In group B, only 33.33% of patients required two sessions and 66.67% of patients had complete success, whereas 20 and 13.33% of patients showed partial and no response, respectively.

These results are consistent with that of Hussein *et al.* [21], who needed more than one session of electrocautery to achieve successful airway patency, and 58.6% of patients had complete recanalization whereas 41.4% of studied group had unfavorable outcome.

Coulter and Mehta [22] in his study of 47 patient with malignant endobronchial lesions concluded successful airway patency in 89% of all obstructions after electrocauterization of obstructing lesions. Also, You *et al.* [23] achieved electrocautery airway reopening in 84% of their studied patients and decrease in the obstruction size up to 47.8%.

In another study, Hetzel *et al.* [24] used a flexible bronchoscope for palliative recanalization of 60 patients using cryoprobe and stated complete and partial response in 61 and 22% of the patients, respectively. Mohammad *et al.* [25] reported more than 50% lumen recanalization in 85% of patients, partial success in 15% of cases, and no failed cases after bronchoscopic cryosurgery usage in malignant endobronchial lesions. Lyu *et al.* [26] revealed cryosurgery airway canalization in 37% of cases and partial response in 50% of cases.

In this study, manageable and few nonlethal complications were met in both groups, as seen in 33.33% in group A and 33.33% in group B; they ranged between hemoptysis and fever, with one case of airway perforation.

In a study by Shehata *et al.* [3], complications of electrocautery were seen in 55.5% of patients in one group such as pneumothorax and esophagitis. In another study, Hooper and Jackson *et al.* [27] reported frightened airway during electrocauterization firing, and this event had its effect in limiting the authors usage of electrocautery in airway lesions management till a near-time.

Hosni *et al.* [17] reported few complications in their study owing to electrocautery usage: bleeding in 4% of cases and pneumomediastinum in 1% of cases.

Lyu *et al.* [26] conducted a study of 30 patients after usage of cryosurgery in endobronchial lesions and reported bleeding in 23.3% of cases during and after

the procedure that necessitated electrocautery applications to manage that complications.

A large-scale study by Maiwand and Asimakopoulos [19] included 521 patients who received endobronchial cryosurgery for airway obstructing lesions; complications were met in 47 patients, consisting of 21 (4%) cases of hemoptysis, 12 (2%) cases of postoperative atrial fibrillation, and 16 cases of respiratory distress.

This study was conducted on a limited number of patients and was one of the limitations of this work; another limitation was no relation between the type of the tumor tissue and the used procedure which may affect the response and outcome. Moreover, the age of the patients may affect patient response to each procedure. The few studies that compare the outcome of both procedures and also the short duration of follow-up (3 weeks) were considerable limitations of this study.

Conclusion

Bronchoscopic cryosurgery and electrocautery are two different techniques used for management of endobronchial lesions, and they have a role in palliative treatment of malignant central airway lesions. Each of these procedure has its own advantages and disadvantages.

Cryosurgery is safe and easy applicable with good outcome but needs longer time and repeated sessions to produce its effect, whereas electrocautery is rapid, lifesaving in many situations, cheap in cost, and is highly effective after short time of heat application that alleviates patients' symptoms after a while and improves their quality of life, but it has some complications and needs perfect training and good patients selection.

Financial support and sponsorship

Nil.

Conflicts of interest

There are no conflicts of interest.

References

- Miyazawa T, Miyazu Y, Iwamoto Y, Ishida A, Kanoh K, Sumiyoshi H, et al. Stenting at the flow-limiting segment in tracheobronchial stenosis due to lung cancer. *Am J Respir Crit Care Med* 2004; **169**:1096–1102.
- Sindhvani G, Rawat J, Keserwani V. Role of endobronchial electrocautery in management of neoplastic central airway obstruction: initial experience with seven cases. *Indian J Chest Dis Allied Sci* 2012; **54**:165–168.
- Shehata SM, El-Shora AE, Mazroaa MA, Ragab MI. Outcome of endobronchial electrocautery versus external beam radiotherapy or both together in the palliative management of non-small cell lung cancer. *Egypt J Chest Dis Tuberc* 2013 **62**:173–181.
- Bolliger CT, Mathur PN, Beamis JF, Becker HD, Cavaliere S, Colt H, et al. ERS/ATS statement on interventional pulmonology. *European Respiratory Society/American Thoracic Society. Eur Respir J* 2002; **19**:356–373.
- Crosta C, Spaggiari L, De Stefano A, Fiori G, Ravizza D, Pastorino U. Endoscopic argon plasma coagulation for palliative treatment of malignant airway obstructions: early results in 47 cases. *Lung Cancer* 2001; **33**:75–80.
- Lee J, Park YS, Yang SC. The endoscopic cryotherapy of lung and bronchial tumors: a systematic review – can we expect a new era of cryotherapy in lung cancer? *Korean J Intern Med* 2011; **26**:132–134.
- Boxem T, Muller M, Venmans B, Postmus P, Sutedja T. Nd-YAG laser vs. bronchoscopic electrocautery for palliation of symptomatic airway obstruction: a cost-effectiveness study. *Chest* 1999; **116**:1108–1112.
- Neel HB 3rd, Farrell KH, DeSanto LW, Payne WS, Sanderson DR. Cryosurgery of respiratory structures. I. Cryonecrosis of trachea and bronchus. *Laryngoscope* 1973; **83**:1062–1071.
- Maiwand MO. Cryotherapy for advanced carcinoma of the trachea and bronchi. *Br Med J (Clin Res Ed)* 1986; **293**:181–182.
- Mallick I, Sharma SC, Behera D. Endobronchial brachytherapy for symptom palliation in non-small cell lung cancer – analysis of symptom response, endoscopic improvement and quality of life. *Lung Cancer* 2007; **55**:313–318.
- American Thoracic Society. Dyspnea: mechanisms, assessment, and management: a consensus statement. *Am J Respir Crit Care Med* 1999; **159**:321–340.
- Morice RC, Ece T, Ece F, Keus L. Endobronchial argon plasma coagulation for treatment of hemoptysis and neoplastic airway obstruction. *Chest* 2001; **119**:781–787.
- Walsh DA, Maiwand MO, Nath AR, Lockwood P, Lloyd MH, Saab M. Bronchoscopic cryotherapy for advanced bronchial carcinoma. *Thorax* 1990; **45**:509–513.
- Mohammad KH, El Badrawy NMS, Hewidy AA, Fouda AM. Sequential use of cryoextraction postelectrocautery for airway recanalization using fiberoptic bronchoscopy. *Egypt J Bronchol* 2015; **5**:269–275.
- Reichle G, Freitag L, Kullmann HJ, Prenzel R, Macha HN, Farin G. Argon plasma coagulation in bronchology: a new method – alternative or complementary? *Pneumologie* 2000; **54**:508–516.
- Breitenbucher A, Chhajed PN, Brutsche MH, Mordasini C, Schilter D, Tamm M. Long-term follow-up and survival after Ultraflex stent insertion in the management of complex malignant airway stenoses. *Respiration* 2008; **75**:443–449.
- Hosni H, Safwat T, Khattab A, Abdel Sabour M, Abdel Rahman G, Nafie A, et al. Interventional bronchoscopy. *Egypt J Bronchol* 2007; **1**:29–37.
- Kvale PA, Simoff M, Prakash UB. American College of Chest P. Lung cancer. Palliative care. *Chest* 2003; **123**(Suppl):284S–311S.
- Maiwand MO, Asimakopoulos G. Cryosurgery for lung cancer: clinical results and technical aspects. *Technol Cancer Res Treat* 2004; **3**:143–150.
- Asimakopoulos G, Beeson J, Evans J, Maiwand MO. Cryosurgery for malignant endobronchial tumors: analysis of outcome. *Chest* 2005; **127**:2007–2014.
- Hussein RMM, Korraa EDA, Fawzy MA, Sileem AE. Prognostic factors for bronchoscopic electrocautery and/or argon plasma coagulation in patients with central airway obstruction. *Egypt J Chest Dis Tuberc* 2013; **62**:501–511.
- Coulter TD, Mehta AC. The heat is on: impact of endobronchial electrosurgery on the need for Nd-YAG laser photoresection. *Chest* 2000; **118**:516–521.
- You HJ, Choi PR, Park EH, Yang JH, Choi IS, Kim HJ, et al. Bronchoscopic electrocautery with electroprobe and diathermic snare in patients with malignant airway obstruction. *Tuberc Respir Dis* 2005; **59**:504–509.
- Hetzel M, Hetzel J, Schumann C, Marx N, Babiak A. Cryorecanalization: a new approach for the immediate management of acute airway obstruction. *J Thorac Cardiovasc Surg* 2004; **127**:1427–1431.
- Mohammad YA, Mahfouz T, Fadl AAE. *Evaluation of the role of APC and cryotherapy in management of endobronchial tumors*. Assuit: Faculty of Medicine: Assuit University; 2007.
- Lyu J, Song JW, Hong SB, Oh YM, Shim TS, Lim CM, et al. Bronchoscopic cryotherapy in patients with central airway obstruction. *Tuberc Respir Dis* 2010; **68**:6–9.
- Hooper RG, Jackson FN. Endobronchial electrocautery. *Chest* 1985; **87**:712–714.