

# Young man with nonresolving pneumonia

Nithya Haridas<sup>a</sup>, Asmita Mehta<sup>a</sup>, Tajik S. Mohammed<sup>a</sup>, Indu R. Nair<sup>b</sup>

Hamartoma is a benign lung tumor. Parenchymal hamartomas are usually asymptomatic, but endobronchial hamartoma can present with features of obstruction. Here, we present a case of a young man who presented with nonresolving pneumonia. His bronchoscopy showed an endobronchial hamartoma.

*Egypt J Bronchol* 2018 12:367–369

© 2018 Egyptian Journal of Bronchology

*Egyptian Journal of Bronchology* 2018 12:367–369

**Keywords:** bronchoscopy, hamartoma, nonresolving pneumonia

## Introduction

Most tumors that involve the tracheobronchial tree are malignant. Benign tumors account for less than 1% of all lung tumors. Among these hamartomas constitute the commonest benign tumor of the tracheobronchial tree [1]. Hamartomas can be intraparenchymal or endobronchial. Endobronchial hamartomas are rare accounting for 1.4% of all hamartomas [2]. Here we describe a case of endobronchial hamartoma.

## Case report

A 28-year-old man presented with complaints of dry cough of 1 month duration, left-sided chest pain, low-grade fever which lasted for 2 days 2 weeks back. He gave a history of loss of weight of ~2 kg in the past 1 month. He did not have any addictions. On examination, he was hemodynamically stable with decreased breath sounds in the left supraclavicular area and suprascapular area. Initial blood investigations were unremarkable with chest radiograph showing a homogeneous opacity in the left upper zone (Fig. 1).

Computed tomography of the chest showed a large spiculated lesion in the apical segment of the left upper lobe (6.8×3.5×1.5 cm) with satellite nodules (1.1×0.6 cm) and slightly enlarged adjacent prevascular lymph nodes (1.1×0.7×1.1 cm). The patient was subjected to bronchoscopy which showed a smooth polypoidal intraluminal growth completely occluding the anterior segment of the left upper lobe and partial occlusion of apicoposterior segment (Fig. 2).

Histopathology (Fig. 3) of the bronchial biopsy specimen showed a hamartomatous lesion.

As the patient had features of obstructive pneumonia, he was subjected to a video-assisted thoracic surgery

Departments of, <sup>a</sup>Pulmonary Medicine, <sup>b</sup>Pathology, Amrita Institute of Medical Sciences, Amrita Vishwa Vidyapeetham, Ponekkara, Kochi, Kerala, India

Correspondence to Nithya Haridas, MD, Department of Respiratory Diseases, Amrita Institute of Medical Sciences, Amrita Vishwa Vidyapeetham, Ponekkara, Kochi 682041, Kerala, India. Tel: 91-848-2858650(office) 91-484-2435651(residence); fax: 91-484-2802020; e-mail: nithyahaaridas@aims.amrita.edu

**Received** 28 September 2017 **Accepted** 21 January 2018

left upper lobectomy. Histopathology of the lobectomy specimen showed chondroid hamartoma with organizing pneumonia due to obstruction of the bronchus.

## Discussion

Hamartomas are benign tumors of the lung which develop in the fibrous connective tissue of the bronchus and may contain cartilage, bone, fat, smooth muscle, and respiratory endothelium [3]. Though initially believed to be a developmental anomaly, recent cytogenetic studies have shown chromosomal bands of recombination located at positions 6p21 and 14q24, suggesting that hamartomas are mesenchymal clonal neoplasms [4].

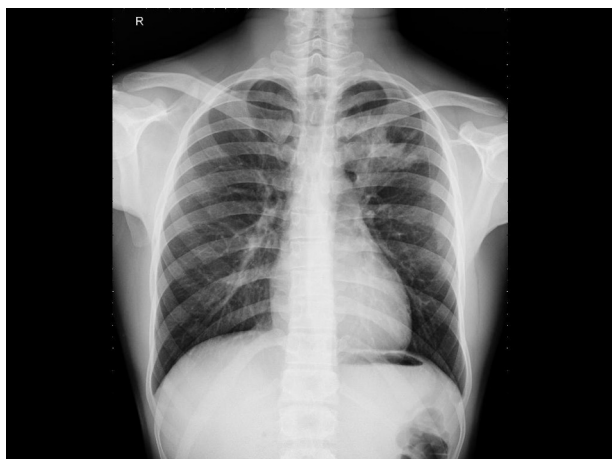Hamartomas are 2–4 times more common in men compared with women. The disease usually occurs in the sixth and seventh decades of life [1]. Since the majority of the lung hamartomas are parenchymal, patients are usually asymptomatic. But patients with endobronchial hamartomas can present with symptoms related to airway obstruction such as cough, hemoptysis, dyspnea, fever, etc. They can have recurrent pneumonia or atelectasis on imaging. Hamartomas are benign tumors with low risk for malignancy [5].

Parenchymal hamartomas usually contain chondroid (80%), fibroblastic (12%), fatty (5%), and osseous tissues (3%). Endobronchial hamartomas can be chondroid (50%), fatty (33%), and fibroblastic (8%) [3].

---

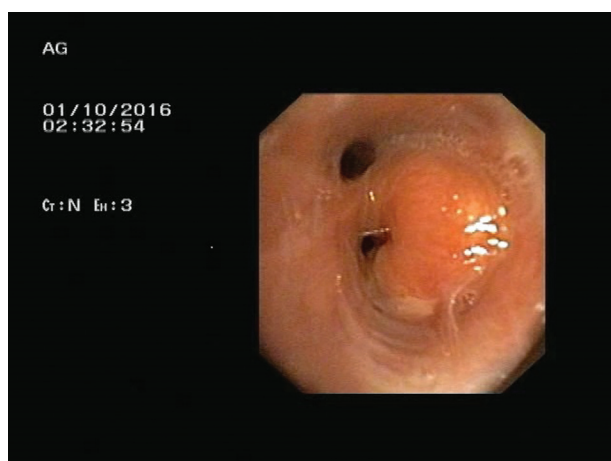
This is an open access journal, and articles are distributed under the terms of the Creative Commons Attribution-NonCommercial-ShareAlike 4.0 License, which allows others to remix, tweak, and build upon the work non-commercially, as long as appropriate credit is given and the new creations are licensed under the identical terms.

Figure 1



Chest radiograph at presentation.

Figure 2

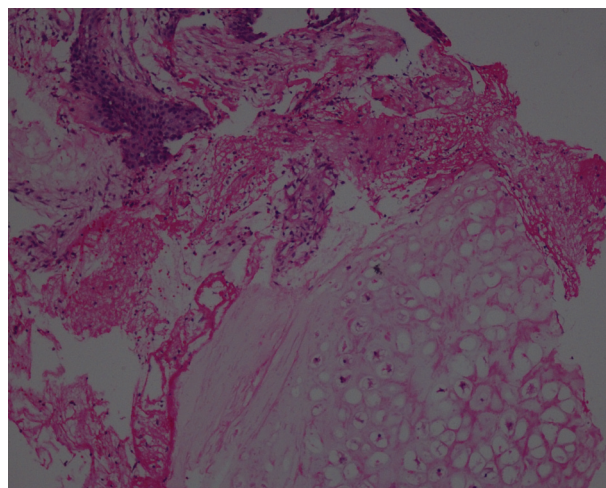


Smooth polypoidal mass occluding the anterior and apicoposterior segment of the left upper lobe.

Pulmonary hamartomas are usually asymptomatic and are found incidentally on chest radiograph [6]. Endobronchial hamartomas can be asymptomatic in the early stages, but can later present with hemoptysis and features of obstructive pneumonia. Here our patient presented with features suggestive of obstructive pneumonia.

Hamartomas are diagnosed by imaging (chest radiography /computed tomography). Parenchymal hamartomas present as solitary pulmonary nodule with smooth or slightly lobulated edges. Though popcorn calcification is the typical diagnostic feature, it may be seen only in 5–50% of the cases [7,8]. Bronchoscopically, endobronchial hamartoma appears as a smooth, polypoidal, or pedunculated neoplasm with a yellowish surface. Biopsy helps in differentiating it from other benign neoplasms and carcinoids [9].

Figure 3



Histopathology image of the bronchial biopsy specimen.

Early diagnosis and treatment of endobronchial hamartoma is the key to prevent postobstructive lung damage and preserve distal lung function. The patient may be subjected to surgical or bronchoscopic resection based on the operability of the patient, size of the tumor, and the degree of distal lung damage. Surgical resection used to be the traditional gold standard for the treatment of endobronchial hamartoma. With the advent of newer bronchoscopic techniques, surgical resection has been replaced by bronchoscopic resection using Argon plasma coagulation and YAG laser because they have a low risk compared with surgery [10]. Endobronchial hamartoma has a low recurrence rate when completely resected. But relapses can occur after endobronchial resection as endobronchial resections can be incomplete due to tumor growth into the bronchus wall. Surgery is the treatment of choice when the tumor is diagnosed late or when irreversible lung damage has already occurred. Prognosis of endobronchial hamartoma is good. Most hamartomas grow slowly, and risk of malignancy is low.

#### Declaration of patient consent

The authors certify that they have obtained all appropriate patient consent forms. In the form the patient(s) has/have given his/her/their consent for his/her/their images and other clinical information to be reported in the journal. The patients understand that their names and initials will not be published and due efforts will be made to conceal their identity, but anonymity cannot be guaranteed.

**Financial support and sponsorship**

Nil.

**Conflicts of interest**

There are no conflicts of interest.

**References**

- 1 Murray J, Kielkowski D, Leiman G. The prevalence and age distribution of peripheral pulmonary hamartoma in adult males: an autopsy based study. *S Afr Med J* 1991; **79**:247–249.
- 2 Gjevre JA, Myers JL, Prakash UB. Pulmonary hamartomas. *Mayo Clin Proc* 1996; **71**:14–20.
- 3 Kang MW, Han JH, Yu JH, Kim YH, Na MH, Yu JH, *et al.* Multiple central endobronchial chondroid hamartomas. *Ann Thor Surg* 2007; **83**:691–693.
- 4 Fletcher JA, Pinkus GS, Donovan K, Naeem R, Sugarbaker DJ, Mentzer S, *et al.* Clonal rearrangement of chromosome band 6p21 in the mesenchymal component of pulmonary chondroid hamartoma. *Cancer Res* 1992; **52**:6224–6228.
- 5 Bini A, Grazia M, Petrella F, Chittolini M. Multiple chondromatous hamartomas of the lung. *Inter Cardiovas Thor Surg* 2002; **1**:78–80.
- 6 Cosio BG, Villena V, Echave-Sustaeta J, de Miquel E, Alfaro J, Hernandez L, *et al.* Endobronchial hamartoma. *Chest* 2002; **122**:202–205.
- 7 Siegelman SS, Khouri NF, Scott WW Jr, Leo FP, Hamper UM, Fishman EK, *et al.* Pulmonary hamartoma: CT findings. *Radiology* 1986; **160**:313–317.
- 8 Ledor K, Fish B, Chaise L, Ledor S. CT diagnosis of pulmonary hamartomas. *J Comput Assist Tomogr* 1981; **5**:343–344.
- 9 Stey CA, Vogt P, Russi EW. Endobronchial lipomatous hamartoma. A rare cause of bronchial occlusion. *Chest* 1998; **113**:254–255.
- 10 Ferreira D, Almeida J, Parente B, Moura ESJ. Complete resection of endobronchial hamartomas via bronchoscopic techniques, electrocautery by Argon plasma and laser. *Rev Port Pneumol* 2007; **13**:711–719.