

# Ultrasound-guided pleurodesis with doxycycline in patients with hepatic hydrothorax

Ahmed M. Abd El Hafeez<sup>a</sup>, Waleed F. Fathallah<sup>b</sup>

**Background** Pleural effusion is a relatively uncommon complication of end-stage liver disease, which occurs in less than 10% of the patients. Patients with refractory hydrothorax require more invasive management with options such as repeated thoracentesis in selected patients, which usually carries risk for pneumothorax and contamination. Many studies have shown that doxycycline pleurodesis is an effective and safe method for achieving apposition of the pleural surfaces.

**Patients and methods** This prospective study included 60 patients with hepatic hydrothorax. All patients were subjected to repeated thoracentesis (two to four times) followed by the placement of a 16-G cannula under ultrasound guidance for proper drainage of any detected remnants of pleural fluid collections. In total, 10 ml of lidocaine 2% were injected in the pleural space followed by 1000 mg of doxycycline diluted in 100 ml saline solution. Pleurodesis session was repeated after 1 week if any radiological evidence for reaccumulation was noticed.

**Results** The sclerotherapy procedure was successful in 46 out of 60 cases (76.7%); the success rate was 72.2% in

massive effusion and reached 83.3% in moderate effusion. A total of 26 patients (43.3%) had to repeat the procedure for a second time, 14 of which (23.3%) failed despite the second trial and 12 cases (20%) showed no fluid reaccumulation.

**Conclusion** Ultrasound-guided doxycycline sclerotherapy is an effective approach for a successful pleurodesis in hepatic hydrothorax (overall rate of 76.7%). The procedure is safe and precludes the need for intercostal tube insertion and thus offering less discomfort for patients. *Egypt J Broncho* 2016 10:20–25

© 2016 Egyptian Journal of Bronchology.

*Egyptian Journal of Bronchology* 2016 10:20–25

**Keywords:** doxycycline, pleurodesis, ultrasound

<sup>a</sup>Department of Chest, <sup>b</sup>Department of Tropical Medicine, Faculty of Medicine, Cairo University, Cairo, Egypt

Correspondence to Ahmed M. Abd El Hafeez, MD, Department of Chest Diseases, Faculty of Medicine, Cairo University, 4 Esraa St., Agouza, 12656 Giza, Egypt.

Tel: 0236922849;

e-mail: medy742000@gmail.com

**Received** 07 September 2015 **Accepted** 18 October 2015

## Introduction

Pleural effusion is a relatively uncommon complication of end-stage liver disease, which occurs in less than 10% of the patients, typically located on the right side in ~70–80% of the cases. Although right-sided pleural effusion can develop in the absence of significant ascites, coexisting ascites is normally present. The negative intrathoracic pressure draws ascitic fluid into the pleural space through the multiple natural defects in the diaphragm, like the ‘pores of Kohn’ [1].

The underlying mechanisms for hepatic hydrothorax are similar to those leading to fluid accumulation and ascites in portal hypertension. Portal hypertension and splanchnic vasodilation plays an important role in the formation of ascites. Several mechanisms have been postulated for the development of hepatic hydrothorax in patients with liver cirrhosis. These include the transfer of the peritoneal fluid into the pleural space through diaphragmatic defects, hypoalbuminaemia resulting in decreased colloid osmotic pressure and lymphatic leakage from the thoracic duct [2]. The direct passage of fluid from the peritoneal to the pleural cavity through diaphragmatic defects has been proposed as the most accepted mechanism explaining most cases of hepatic hydrothorax [3,4].

The composition of hepatic hydrothorax is transudative in nature and therefore similar to the ascitic fluid; it also has a serum to pleural fluid albumin gradient greater than 1.1, as is found in ascites secondary to portal hypertension. Other tests from the pleural fluid that would be appropriate depending on the clinical circumstances include triglycerides, pH, adenosine deaminase and PCR for mycobacteria, amylase and cytology, to exclude chylothorax, empyema, tuberculosis, pancreatitis, and malignancy, respectively. These additional tests should be considered when the fluid is an exudate or when the pleural effusion is left-sided [5].

The management of hepatic hydrothorax is difficult. Medical measures include sodium restriction with a combination of diuretics (furosemide and spironolactone), which increases in stepwise fashion according to response [6]. Some studies advocated the use of combination of midodrine and octreotide in the treatment of hepatic hydrothorax [7].

---

This is an open access article distributed under the terms of the Creative Commons Attribution-NonCommercial-ShareAlike 3.0 License, which allows others to remix, tweak, and build upon the work non-commercially, as long as the author is credited and the new creations are licensed under the identical terms.

Patients with refractory hydrothorax require more invasive management with options such as repeated thoracentesis in selected patients, which usually carries risk for pneumothorax and contamination [8]. Transjugular intrahepatic portosystemic shunt is another option together with pleurodesis and repair of defects in the diaphragm. However, the majority of these patients with hepatic hydrothorax have advanced liver disease and may be potential candidates for orthotopic liver transplantation [9].

Pleurodesis is a procedure in which the space between the visceral and parietal pleura is obliterated with the use of an agent that acts as an irritant to cause inflammation on the pleural surfaces. The irritant is usually administered through a chest tube or during thoracoscopy (medical or VATS) [10]. On the other hand, the technique can sometimes be challenging for achieving pleurodesis in hepatic hydrothorax because of the rapid fluid accumulation [11].

To date, a large number of chemicals have been considered to induce pleurodesis in malignant or nonmalignant effusions. Although talc, tetracycline derivatives, OK-432, bleomycin or povidone-iodine are the most commonly used agents for liver-related pleurodesis, availability, side effects and variable results are still major concerns [12].

In the literature, many factors have been reported to influence the results of pleurodesis, such as re-expansion of the compressed lung, the characteristics of the pleural effusion (pH, glucose, LDH), the amount of fluid drainage per day and the types of sclerosing agents [13]. Many studies showed that doxycycline pleurodesis is an effective and safe method for achieving apposition of the pleural surfaces [14].

Recently, image-guided percutaneous small-bore catheter drainage of accumulated fluid has been proved to be useful and successful [15].

### **Aim of the study**

The aim of the present study was to detect the efficacy of ultrasound-guided pleurodesis using doxycycline as a sclerosing agent.

### **Patients and methods**

This prospective study included 60 patients with clinical, laboratory and radiological evidence of liver cirrhosis complicated by hepatic hydrothorax, and who were admitted to Chest and Tropical Departments of the Cairo University Hospital during the period from March 2010 to November 2014.

All patients were kept on close medical management in the form of intravenous albumin, sodium and fluid restriction, and proper diuretic therapy. Exclusion criteria included hepatic encephalopathy, massive ascites or evidence of portal vein thrombosis.

The study included 44 men (73.3%) and 16 women patients (26.7%) with an age range between 41 and 65 years. All patients were subjected to repeated thoracentesis two to four times according to the size and rate of reaccumulation of the effusion, provided that the maximum amount of drained fluid per session did not exceed 2000 ml. Serial thoracentesis sessions were separated by at least 1 day in-between. Adequate fluid evacuation and lung re-expansion were radiologically and ultrasonically confirmed.

After attaining the best lung expansion, the placement of a 16-G cannula for proper drainage of any detected remnants of pleural fluid collections was carried out under ultrasound guidance. Proper evacuation was attempted with a maximum amount of 100 ml allowed to stay in the pleural space. Ten milliliters of lidocaine 2% were injected in the pleural space, followed by injecting 1000 mg doxycycline in 100 ml of isotonic sodium chloride under sterile conditions. Patients were then asked to change their body position every 15 min for 2 h after the procedure to allow for proper distribution of doxycycline.

Chest radiographs were obtained 2 h after the procedure, every other day for 1 week and then once weekly for 3 months.

Medical treatment was continued with special regard to albumin compensation, salt restriction and diuretic therapy during the follow-up period.

If any radiological evidence for reaccumulation was noticed, another pleurodesis session with the same steps was attempted after 1 week with continued medical treatment.

The response of pleurodesis was defined on the basis of chest radiograph findings at 3-month follow-up as follows:

- (1) Successful – that is, no reaccumulation of pleural effusion.
- (2) Failure – that is, any fluid reaccumulation after two trial sessions for pleurodesis.

### **Statistical analysis**

- (1) All data were collected, summarized, presented and analyzed by using an appropriate statistical package program (SPSS version, 10).
- (2) Quantitative data were summarized as mean and SD.

- (3) Qualitative data were summarized as number and percentage.
- (4) Test of significance used for quantitative data for two groups was the *t*-test.

#### Level of significance

$P > 0.05$ : NS (nonsignificant).

$P < 0.05$ : S (significant).

$P < 0.01$ : HS (highly significant) [16].

### Results

In our study, 44 men (73.3%) and 16 women (26.7%) were included with an age range between 41 and 65 years with a mean of 54.2 years.

Cases were classified according to the amount of pleural fluid into following:

- (1) Massive effusion – that is, pleural fluid reaching above second intercostal space anteriorly ( $N = 36$ , i.e. 60%).
- (2) Moderate effusion – that is, pleural fluid reaching between second and fourth intercostals spaces anteriorly ( $n = 24$ , i.e. 40%).

Cases with minimal pleural effusion were not included in this study.

Table 1 illustrates the relation between the amount of effusion with the rate of success of the procedure, complications and the need to repeat the pleurodesis session.

The sclerotherapy procedure was successful in 46 out of 60 cases (76.7%); the success rate was 72.2% in massive effusion and reached 83.3% in moderate effusion with no significant difference between the two groups ( $P > 0.05$ ).

A total of 26 patients (43.3%) had to repeat the procedure for a second time, 14 of which (23.3%) failed despite the second trial, and 12 cases (20%) showed no fluid reaccumulation.

Out of the 14 patients with unsuccessful pleurodesis, eight cases presented with mild to moderate encysted pleural effusion below the initial presentation and did not require thoracentesis for respiratory distress. In the other six cases, fluid reaccumulation reached the level of initial presentation and required thoracentesis for respiratory distress.

Mean presclerotherapy serum albumin level (1 day before pleurodesis) was  $3.02 \pm 0.271$  g/dl in cases with successful pleurodesis, with no significant difference ( $P > 0.05$ ) from cases with failed pleurodesis who had mean presclerotherapy serum albumin level of  $2.85 \pm 0.286$  g/dl (Fig. 1).

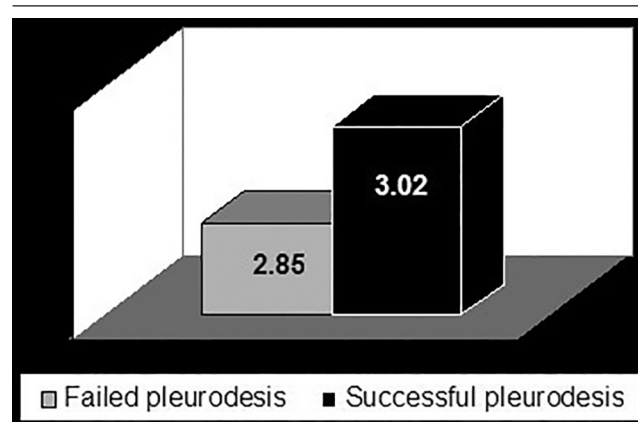
No morbidity-related or mortality-related events were recorded in any of our cases with sonographic-guided doxycycline pleurodesis.

### Discussion

Traditional treatment of hepatic hydrothorax in a patient who fails to respond to aggressive medical management of ascites remains problematic and controversial. Review of the literature has revealed that no method is ideal at present. Although thoracentesis is the most effective method for rapid relief of dyspnea secondary to massive pleural effusion associated with hepatic hydrothorax, it carries the risk of substantial protein depletion without preventing fluid reaccumulation, especially if repeated thoracentesis is required [17].

Placement of a chest tube usually results in uncontrollable fluid loss and has a high mortality rate [18]. Although some pulmonologists still advocate this, even in their experienced hands mortality is high and the chest tube cannot be removed in a considerable number of patients [19]. Runyon and colleagues reported two deaths resulting from associated massive protein and electrolyte depletion. In addition,

Fig. 1



Preprocedure albumin level.

Table 1 Yield of doxycycline pleurodesis in moderate and massive effusions

	Massive effusion (36 patients) [n (%)]	Moderate effusion (24 patients) [n (%)]	Total cases (60 patients) [n (%)]
Repeated pleurodesis sessions	17/36 (47.2)	9/24 (37.5)	26/60 (43.3)
Complications	Nil	Nil	Nil
Success rate	26/36 (72.2)	20/24 (83.3)	46/60 (76.7)

prolonged drainage through the chest tube may cause renal failure, impaired immunological functions and iatrogenic infection as common sequelae [20].

Pleurodesis following pleural aspiration decreases the chance of pleural effusion recurrence, and has been a widely used, long-standing method of controlling recurrent pleural effusions [21]. In traditional pleurodesis using a large-bore chest tube or small-bore catheter thoracostomy, sclerotherapy is usually performed when the pleural fluid is adequately drained, the compressed lung is in full re-expansion and the daily volume of fluid drainage is below 100–150 ml [22].

Many studies showed that doxycycline pleurodesis is an effective and safe method for achieving apposition of the pleural surfaces [14]. In this study, ultrasound-guided pleurodesis was attempted on 60 patients. Doxycycline was the sclerosing agent in all cases.

Complete control of the effusion was achieved in 46 cases (76.7%). Fluid reaccumulation occurred in 14 patients (23.3%); the success rate was 72.2% in massive effusion and reached 83.3% in moderate effusion with no significant difference between the two groups ( $P > 0.05$ ). A total of 26 patients (43.3%) had to repeat the procedure for a second time, 14 of which (23.3%) failed despite the second trial and 12 cases (20%) showed no fluid reaccumulation (Table 1 and Fig. 2).

Aydogmos and colleagues (2009) observed that pleurodesis success was significantly decreased if time between the first diagnosis of effusion and onset of chest tube drainage was longer than 30 days. This may be explained by the progression of pleural disease or fibrosis of the visceral pleura. Similarly, success rate was lower if the time between chest tube drainage and pleurodesis was longer than 5 days, although not statistically significant [23]. In our study, a success rate

of 83.3% was achieved in moderate effusions, whereas a success rate of 72.2% was observed in massive effusions. The success rate was nonsignificantly affected by the initial effusion size ( $P > 0.05$ ).

Tetracycline was, until 1998, the most popular and widely used sclerosing agent through an intercostal tube in the UK when its production was discontinued by the manufacturer following its discontinuation in the USA in 1992 [24]. Tetracycline may still be imported from Europe (Germany) at present, but this supply may also cease in the near future. Tetracycline has a modest efficacy (average success rate: 65%), an excellent safety profile and it is relatively inexpensive. It is well tolerated and its side effects are infrequent, mild and transient [13].

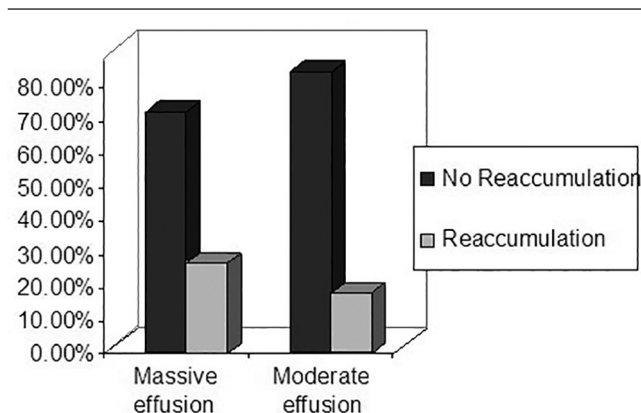
Doxycycline has been proposed as an alternative to tetracycline with a similar success rate ranging from 25 to 100% [25]. Doxycycline was used instead of tetracycline in our study to avoid its hepatorenal toxicity [26]. The major disadvantage to the use of doxycycline is the need for repeated instillations to obtain a satisfactory response. The associated prolonged intercostal tube indwelling time potentially increases patient discomfort, the risk of infection and overall treatment cost [27].

Data are limited regarding the appropriate dosage and regimen of doxycycline. Comparative trials with alternative agents are lacking; the majority of the data are retrospective in nature and involve small numbers of patients [28]. In the published literature, the dose of doxycycline varied from 500 to 1000 mg per instillation; in some cases single doses were used, while in others instillations were repeated if pleural fluid drainage remained excessive. The dose was diluted in 25–100 ml of normal saline [29]. Doxycycline was effective in achieving pleurodesis in patients with pleural effusions and was well-tolerated, with mild adverse effects of transient fever and pleural pain with instillation [30].

Talc has been proven to be one of the most effective sclerosing agents for treating malignant pleural effusion [22]. Success rate varies between 88 and 100% [31]. Talc poudrage or slurry is usually well tolerated, and pleuritic chest pain and mild fever are the most common side effects observed. A serious complication associated with the use of talc is acute respiratory distress syndrome or acute pneumonitis [32]. The mechanism of acute talc pneumonitis is unclear. The dose of talc and the physical characteristics (size and type) appear to be the most important determinants for the development of this complication [28].

In a study by Milanez de Campos and colleagues (2000), aerosolized talc was effective in preventing recurrence

Fig. 2



Success rate for pleurodesis.

of the effusion in only 10 patients (47.6%). Effusions recurred within 3 months in 43.7% of patients; in addition, there were several complications recorded, including fever, chest pain, empyema, incomplete re-expansion, pneumonia and wound infection [17].

Lee and colleagues (2011) performed chemical pleurodesis using talc and viscum album through intercostal tube insertion in 11 patients with hepatic hydrothorax. The initial success of treatment was achieved in eight out of 11 patients (72.7%), mild complications such as fever/leucocytosis occurred in all enrolled patients and a significant proportion of patients experienced more severe complications such as pneumonia (9.1%), pneumothorax (36.4%), azotaemia/acute renal failure (54.6%) and hepatic encephalopathy (36.4%). Five patients (45.5%) were suspected to have procedure-related mortality due to the occurrence of these devastating complications [33].

Bleomycin is the most widely used antineoplastic agent for sclerotherapy. Its mechanism of action is predominantly as a chemical sclerosing agent similar to tetracycline and sterile talc. It is an effective sclerosant with an average success rate of 60% and has an acceptable side effect profile. However, its major limitation is the cost per treatment [13].

The efficacy of pleurodesis with iodopovidone was 91.6% in a study conducted by Morales-Gomez *et al.* [34], and 64.2% in a study conducted by Kelly-Garcia *et al.* [35]. This is comparable to our results with doxycycline as a sclerosing agent (success rate: 76.7%), but in both the above studies, pleurodesis was performed through tube thoracostomy, which is contrary to our work where ultrasound-guided pleurodesis was attempted without resorting to intercostal tube insertion.

Olivares-Torres and colleagues administered iodopovidone either through a chest tube or at the time of thoracotomy in 52 patients. Three patients experienced intense pleuritic pain and systemic hypertension after installation of the sclerosing agent, but they recovered without incident [36]. The argument about the use of iodopovidone because of these two complications was explained by the fact that the use of any effective pleural irritant, including talc and iodopovidone, can and will produce intense pleuritic pain and a vasovagal reaction if analgesia and anaesthesia are inadequate, and hence pain control should be individualized [37].

In our study, doxycycline proved to be an extremely effective and safe agent for pleurodesis. No complications were noted in any of our cases with sonographic-guided doxycycline pleurodesis. The efficacy of doxycycline is comparable to that of talc,

but there is no fear of severe complications, such as acute respiratory distress syndrome, which occurs especially if the talc used has a smaller particle size (<15 µm). Moreover, pleurodesis with doxycycline can be performed under local anaesthesia with excellent tolerance and acceptability [38].

## Conclusion

According to our study, ultrasound-guided doxycycline sclerotherapy is an effective approach for a successful pleurodesis in hepatic hydrothorax. The procedure offers high success rate (overall rate of 76.7%), better patient compliance, least complications and precludes the need for intercostal tube insertion, thus offering less discomfort for patients.

## Financial support and sponsorship

Nil.

## Conflicts of interest

There are no conflicts of interest.

## References

- Huang PM, Chang YL, Yang CY, Lee YC. The morphology of diaphragmatic defects in hepatic hydrothorax: thoroscopic finding. *J Thorac Cardiovasc Surg* 2005; **130**:141–145.
- Kirschner PA. Porous diaphragm syndromes. *Chest Surg Clin N Am* 1998; **8**:449–472.
- Mouroux J, Perrin C, Venissac N, Blaive B, Richelme H. Management of pleural effusion of cirrhotic origin. *Chest* 1996; **109**:1093–1096.
- Zenda T, Miyamoto S, Murata S, Mabuchi H. Detection of diaphragmatic defect as the cause of severe hepatic hydrothorax with magnetic resonance imaging. *Am J Gastroenterol* 1998; **93**:2288–2289.
- Lazaridis KN, Frank JW, Krowka MJ, Kamath PS. Hepatic hydrothorax: pathogenesis, diagnosis, and management. *Am J Med* 1999; **107**:262–267.
- Moore KP, Wong F, Gines P, *et al.* The management of ascites: report on the consensus conference of the International Ascites Club. *Hepatology* 2003; **38**:258–266.
- Kalambokis G, Fotopoulos A, Economou M, Tsianos EV. Beneficial haemodynamic and renal sodium handling effects of combined midodrine and octreotide treatment in a cirrhotic patient with large hepatic hydrothorax and mild ascites. *Nephrol Dial Transplant* 2005; **20**:2583.
- Nathan J, Richard N, Chris H, Darcy M. Thoracentesis complication rates on the medical clinical teaching unit: does ultrasonography make a difference? *Chest* 2011; **140**:497A.
- Spencer EB, Cohen DT, Darcy MD. Safety and efficacy of transjugular intrahepatic portosystemic shunt creation for the treatment of hepatic hydrothorax. *J Vasc Interv Radiol* 2002; **13**:385–390.
- Northup PG, Harmon RC, Pruett TL, Schenk WGIII, Daniel TM, Berg CL. Mechanical pleurodesis aided by peritoneal drainage: procedure for hepatic hydrothorax. *Ann Thorac Surg* 2009; **87**:245–250.
- Rodriguez-Panadero F, Montes-Worboys A. Mechanisms of pleurodesis. *Respiration* 2012; **83**:91–98.
- Goto T, Oyamada Y, Hamaguchi R, Shimizu K, Kubota M, Akanabe K, *et al.* Remission of hepatic hydrothorax after OK-432 pleurodesis. *Ann Thorac Cardiovasc Surg* 2011; **17**:208–211.
- Walker-Renard PB, Vaughan LM, Sahn SA. Chemical pleurodesis for malignant pleural effusions. *Ann Intern Med* 1994; **120**:56–64.
- Kvale PA, Selecky PA, Prakash UB. American College of Chest Physicians. Palliative care in lung cancer: ACCP evidence-based clinical practice guidelines (2nd edition). *Chest* 2007; **132**:368S–403S.
- Merriam MA, Cronan JJ, Dorfman GS, Lambiase RE, Haas RA. Radiographically guided percutaneous catheter drainage of pleural fluid collections. *Am J Roentgenol* 1988; **151**:1113–1116.

- 16 Altman DG, Schulz KF, Moher D, Egger M, Davidoff F, Elbourne D, *et al.* The revised CONSORT statement for reporting randomized trials: explanation and elaboration. *Ann Intern Med* 2001; **134**:663–694.
- 17 Milanez de Campos JR, Filho EA, de Campos Werebe E, Sette HJr, Fernandez A, Filomeno LT, *et al.* Thoracoscopy and talc poudrage in the management of hepatic hydrothorax. *Chest* 2000; **118**:13–17.
- 18 Borchardt J, Smirnov A, Metchnik L, *et al.* Treating hepatic hydrothorax. *Br Med J* 2003; **326**:751–752.
- 19 Liu LU, Haddadin HA, Bodian CA, Sigal SH, Korman JD, Bodenheimer HCJr, *et al.* Outcome analysis of cirrhotic patients undergoing chest tube placement. *Chest* 2004; **126**:142–148.
- 20 Runyon BA, Greenblatt M, Ring MHC. Hepatic hydrothorax is a relative contraindication to chest tube insertion. *Am J Gastroenterol* 1986; **81**:566–567.
- 21 Zaloznik AJ, Oswald SG, Langin M. Intrapleural tetracycline in malignant pleural effusions. *Cancer* 1983; **51**:752–755.
- 22 Ruckdeschel JC, Moores D, Lee JY, Einhorn LH, Mandelbaum I, Koeller J, *et al.* Intrapleural therapy for malignant pleural effusions: a randomized comparison of bleomycin and tetracycline. *Chest* 1991; **100**:1528–1535.
- 23 Aydogmos U, Ozdemir S, Cansever L, Sonmezoglu Y, Kocaturk CI, Bedirhan MA. Bedside talc pleurodesis for malignant pleural effusion: factors affecting success. *Ann Surg Oncol* 2009; **16**:745–750.
- 24 Hefner JE, Unruh LC. Tetracycline pleurodesis: adios, farewell, adieu. *Chest* 1992; **101**:64–66.
- 25 Barbetakis N, M Vassiliadis, K Kaplanis, R Valeri, C Tsilikas. Mitoxantrone pleurodesis to palliate malignant pleural effusion secondary to ovarian cancer. *BMC Palliat Care* 2004; **3**:4.
- 26 Pestal M. Doxycycline in the treatment of respiratory tract infections. Results of a pan European multi-centre trial. *Chemotherapy* 1975; **21**:91–108.
- 27 Antunes G, Neville E, Duffy J, Ali N. BTS guidelines for the management of malignant pleural effusions. *Thorax* 2003; **58**:1129–1138.
- 28 Windsor PG, Como JA, Windsor KS. Sclerotherapy for malignant pleural effusions: alternatives to tetracycline. *South Med J* 1994; **87**:709–714.
- 29 Hoffer FA, Hancock ML, Hinds PS, Oigbokie N, Rai SN, Rao B. Pleurodesis for effusions in pediatric oncology patients at end of life. *Pediatr Radiol* 2007; **37**:269–273.
- 30 Putnam JBJr, Light RW, Rodriguez RM, Ponn R, Olak J, Pollak JS, *et al.* A randomized comparison of indwelling pleural catheter and doxycycline pleurodesis in the management of malignant pleural effusions. *Cancer* 1999; **86**:1992–1999.
- 31 Shaw P, Agarwal R. Pleurodesis for malignant pleural effusions. *Cochrane Database Syst Rev* (CDSR) 2004; 1:CD002916.
- 32 Steven AS. Malignant pleural effusion. *Semin Respir Crit Care Med* 2001; **22**:607–615.
- 33 Lee WJ, Kim HJ, Park JH, Park DI, Cho YK, Sohn CI, *et al.* Chemical pleurodesis for the management of refractory hepatic hydrothorax in patients with decompensated liver cirrhosis. *Korean J Hepatol* 2011; **17**:292–298.
- 34 Morales-Gomez J, Tellez-Becerra JL, Martinez-Ormeno JE, Villalba Caloca J. Pleurodesis with iodopovidone in malignant pleural effusions. *Rev Ins Nal Enf Resp Mex* 1993; **6**:71–74.
- 35 Kelly-Garcia J, Roman-Berumen JF, Ibarra-Perez C. Iodopovidone and bleomycin pleurodesis for effusions due to malignant epithelial neoplasms. *Arch Med Res* 1997; **28**:583–585.
- 36 Olivares-Torres CA, Laniado-Laborin R, Chavez-Garcia C, León-Gastelum C, Reyes-Escamilla A, Light RW. Iodopovidone pleurodesis for recurrent pleural effusions. *Chest* 2002; **122**:581–583.
- 37 Brant A, Eaton T. Serious complications with talc slurry pleurodesis. *Respirology* 2001; **6**:181–185.
- 38 Maskell NA, Lee YC, Gleeson FV, Hedley EL, Pengelly G, Davies RJ. Randomized trials describing lung inflammation after pleurodesis with talc of varying particle size. *Am J Respir Crit Care Med* 2004; **170**:377–382.