

# The diagnostic value of ultrasound-guided percutaneous transthoracic core-needle biopsy versus computed tomography-guided biopsy in peripheral intrathoracic lesions

Wafaa S. El-Shimy<sup>a</sup>, Fawzy A. El-Emery<sup>a</sup>, Ayman H. Abd El-Zaher<sup>a</sup>, Amr M. El-Badry<sup>b</sup>, Dalia E. El-Sharawy<sup>a</sup>

**Introduction** Transthoracic ultrasound has become an important diagnostic tool in peripheral intrathoracic lesions. Transthoracic needle biopsy is a relatively safe and easy procedure under real-time ultrasound (US) guidance, and may provide adequate tissue sampling of lesions for cytological, histological, or microbiological analysis.

**Objectives** The aim of the present study was to compare the diagnostic yield, accuracy, and complications of thoracic US-guided core-needle biopsy versus computed tomography (CT)-guided biopsy in peripheral intrathoracic lesions, including pleural, peripheral pulmonary, and mediastinal lesions.

**Patients and methods** US-guided biopsy and CT-guided biopsy were performed in Chest and Radiology Departments during the period from February 2011 to June 2014 on 100 patients (50 patients for each group) using core-biopsy needle, with needle size (16–18–20 G), needle length (20 cm), and core length (1–1.5–2 cm) according to the size and type of lesion. The histopathological examination and complications were reported.

**Results** The diagnostic value of chest US was compared with CT; chest US had sensitivity 91.7%, specificity 89.4%, positive predictive value 73.3%, negative predictive value 97.1%, and accuracy 90% in detecting pleural lesions; 90.7, 91.4, 95.1, 84.2, and 91%, respectively, in detecting

pulmonary lesions; and 72.7, 88.7, 44.4, 96.3, and 87%, respectively, in detecting mediastinal lesions compared with chest CT. After taking transthoracic biopsy, chest US-guided biopsy revealed four benign (8%), 30 malignant (60%), 10 inflammatory (20%), and six undiagnosed (12%) cases, whereas CT group revealed two (4%), 33 (66%), 10 (20%), and five (10%) cases, respectively, with a complication rate [pneumothorax: two (4%) cases for US group and three (6%) cases for CT group and pulmonary hemorrhage: two (4%) cases and three (6%) cases respectively].

**Conclusion** Chest US-guided biopsy is safe, reliable, and a fast procedure with lower cost and fewer complications than is CT-guided biopsy, provided that the lesions have favorable acoustic window and abut the visceral pleura.

*Egypt J Broncho* 2016 10:12–19

© 2016 Egyptian Journal of Bronchology.

*Egyptian Journal of Bronchology* 2016 10:12–19

**Keywords:** computed tomography, core-needle biopsy, thoracic ultrasound

Departments of <sup>a</sup>Chest and <sup>b</sup>Radiology, Faculty of Medicine, Tanta University, Tanta, Egypt

Correspondence to D.E. El-Sharawy, Chest Department, Tanta University Hospitals, El-Geish Street, Tanta, Egypt  
e-mail: dalia-elsharawy@hotmail.com

**Received** 03 July 2015 **Accepted** 18 August 2015

## Introduction

The variety of chest imaging techniques available for patient investigation continues to increase with a substantial improvement in pre-existing techniques; the decision on which technique to employ in disease investigation requires knowledge of their benefits and disadvantages, and information on how successfully these tests have been employed [1].

Computed tomography (CT) is among the more commonly used imaging investigations in patients with chest disease. Modern CT scanners can acquire images of the thorax in a single breath-hold and provide exquisite morphological detail, but the added radiation burden remains a major consideration for physicians and radiologists alike [2].

Ultrasound (US) has been proven to be valuable for the evaluation of a wide variety of chest diseases, particularly when the pleural cavity is involved. The advantages of US

are that it is relatively inexpensive, widely available, and a mobile form of multiplanar imaging free from ionizing radiation. Chest US can supplement other imaging modalities of the chest, and guide a variety of diagnostic and therapeutic procedures. Under real-time US guidance the success rates increase significantly whereas the risks are greatly reduced [3]. Thus, clinically performed chest US is rapidly entering clinical practice in the fields of intensive care, respiratory medicine, and acute medicine [4].

## Patients and methods

The study was carried out at Chest and Radiology Departments, Tanta University Hospitals during

---

This is an open access article distributed under the terms of the Creative Commons Attribution-NonCommercial-ShareAlike 3.0 License, which allows others to remix, tweak, and build upon the work non-commercially, as long as the author is credited and the new creations are licensed under the identical terms.

the period from February 2011 to June 2014. It included 100 patients with undiagnosed peripheral intrathoracic lesions; the origin of the lesions was pleural, pulmonary, or mediastinal as evidenced by chest radiography (posteroanterior and lateral views) and recent contrast-enhanced chest CT, after which all patients were subjected to real-time US (B-K Medical, Denmark) prebiopsy to detect its diagnostic outcome. The patients were divided into two groups:

#### Group I

This group included 50 patients on whom core-needle biopsy (CNB) was carried out guided by real-time US.

#### Group II

It included 50 patients on whom CNB was carried out guided by CT.

An informed written consent was taken from all patients.

#### Inclusion criteria [5]

- (1) New or enlarging solitary pulmonary nodule or mass on the chest radiograph with accessible US window (not under rib or retrosternal) and no intervening normal parenchymal tissue between pleural surface and lesion.
- (2) Multiple pulmonary nodules in a patient not known to have malignancy or who had a prolonged remission.
- (3) Persistent focal infiltrates either single or multiple, for which no diagnosis had been made by sputum or blood culture or serology.
- (4) Parenchymal disease not responding to therapy.
- (5) Parenchymal opacities in an immunocompromised host.
- (6) Peripheral mediastinal mass.
- (7) Pleural mass or diffuse pleural thickening.

#### Exclusion criteria[5]

- (1) Cardiovascular instability – for example, unstable angina, recent myocardial infarction, or uncontrolled severe hypertension.
- (2) Lack of patient cooperation – for example, intractable cough, inability to remain motionless, or altered consciousness.
- (3) Bleeding diathesis (activated partial thromboplastin time ratio or international normalized ratio >1.3 or platelet count <50 000/mm<sup>3</sup>).
- (4) Contralateral pneumonectomy.
- (5) Borderline respiratory failure (SaO<sub>2</sub> 85–90%) and patient on mechanical ventilation.
- (6) Hypervascular lesion or aneurysm.
- (7) Severe chronic obstructive pulmonary disease (FEV<sub>1</sub> <1 l or <35% predicted).
- (8) Pyogenic cutaneous lesion (pyoderma).

#### All patients were subjected to the following

- (1) Thorough history taking and full clinical examination.
- (2) Chest radiograph (posteroanterior and lateral views) before and after the procedure.
- (3) Recent CT (CT chest) with nonionic contrast media before the biopsy.
- (4) Laboratory studies:
  - (a) Complete liver functions.
  - (b) Blood urea and serum creatinine.
  - (c) Complete blood picture.
  - (d) Erythrocyte sedimentation rate.
  - (e) Fasting and postprandial blood sugar.
  - (f) Sputum examination for malignant cells and Ziehl–Neelsen stain for acid fast bacilli on 3 successive days in suspected patients clinically and radiologically.
- (5) Preprocedural evaluation: Pulmonary function tests, arterial blood gases, ECG and coagulation profile (including bleeding and clotting times, prothrombin time, and activity and activated partial thromboplastin time) with the consideration that oral anticoagulants were stopped before the procedure for at least 48 h.
- (6) Chest US for all patients using high resolution real-time US (B-K Medical).
- (7) Color Doppler US by the same device in suspected vascular lesions.
- (8) Clinical and radiological follow-up of patients over 1 week after the procedure to detect the occurrence of any complications.
- (9) The examination of biopsy samples histopathologically.

#### The procedure of ultrasound-guided core-needle biopsy

- (1) The affected region was scanned using US (B-K Medical) with a 3.5-MHz convex probe parallel to the ribs in the intercostal spaces. Local anesthesia was used in every case using local subcutaneous injection of 10–20 ml xylocaine 2%. Deep breaths and coughing were to be avoided during the biopsy procedure [6].
- (2) The core biopsy needle GTA [Quistello (MN), Italy] having a size of 16-, 18-, or 20-G needle, length of 20 cm, and core length of 10, 15 or 20 mm was chosen according to the size and type of the lesion. The needle was placed into the biopsy gun. The puncture was performed using continuous visual control on the monitor. The needle was penetrated just to the nearest border of the lesion. The biopsy was performed by firing the gun [6] (Fig. 1).
- (3) The needle was removed and compression was applied at the puncture site. When the tissue sample was considered sufficient, no further punctures were performed. The number of

samplings was recorded mostly two or three punctures [6] (Fig. 2).

- (4) The sample was placed in a tube containing 4% formaldehyde and was sent to the pathological department [6] (Fig. 3).
- (5) Chest radiograph was performed after the biopsy to rule out any complications. All patients were observed for at least 12 h after the procedure up to 1 week to detect any complications [6].

#### The procedure of computed-tomography-guided core-needle biopsy

- (1) The needle path was chosen considering straight pathway from the skin to lesion. Ideally, the needle should cross the pleura at a 90° angle rather than at an oblique angle with avoidance of transversal of bullae, vessels, and bronchi. The selection of the axial slice most representative of the lesion was made [7].
- (2) CT scanner (Toshiba, X-vision/GX; Japan) allowed low-dose axial scan with 120 kVp and 40 mA or lower per slice. The slice thickness should be less than half the diameter of the targeted lesion to be certain that a single CT image contains the lesion [8].
- (3) With the use of the gantry laser light to delineate the Z-axis position, and radiopaque skin marker to reference the X-axis position, the needle entry site was marked on the patient's skin. The skin site was prepped and draped using sterile technique followed by administration of local anesthesia (local subcutaneous injection of xylocaine 2%) into the skin, subcutaneous tissues, and intercostal muscles [9].
- (4) The same core-biopsy needles (GTA) were used having size of 16, 18, or 20 G with biopsy gun in taking CNB. Then, new axial slices were made to confirm the correct location [9].
- (5) The sample was placed in a tube containing 4% formaldehyde and was sent to the pathological department. After the biopsy, a short CT scan was performed to evaluate patients for immediate complications [10].


#### Results

This study was conducted on 100 patients divided into two groups:

Group I included 50 patients (35 men and 15 women, with an age range of 21–80 years and a mean of 57.39 years  $\pm$  SD 13.4 years), on whom CNB was carried out guided by real-time US.

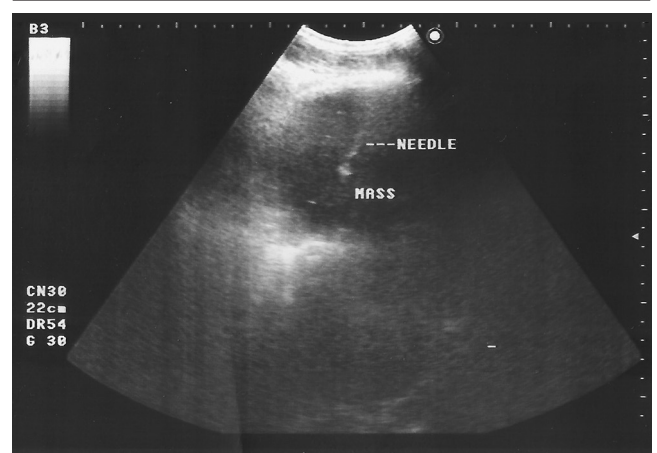
Group II included 50 patients (34 men and 16 women with an age range of 15–83 years and a mean of

Fig. 1



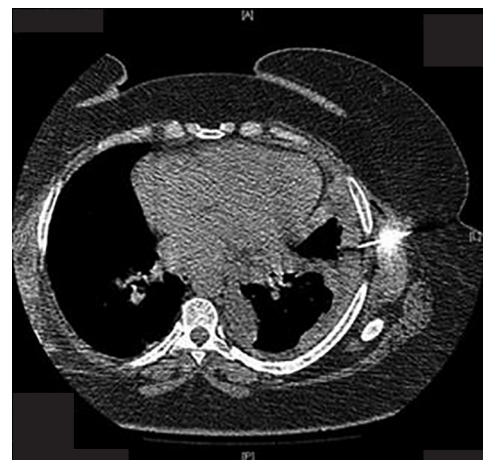The core-biopsy needle GTA and the biopsy gun (used for core-needle biopsy under ultrasound or computed tomography guidance).

Fig. 2



Case no. 2 in group I. Right-sided infrascapular well-defined hypoechoic lesion associated with pleural thickening diagnosed histopathologically as moderately differentiated, grade II, adenocarcinoma.

Fig. 3



Case no. 36 in group II. Left-sided costal and mediastinal irregular pleural thickening with encysted pleural effusion and ipsilateral mediastinal shift diagnosed histopathologically as malignant mesothelioma.

49.02 years  $\pm$  SD 16.3 years), on whom CNB was carried out guided by CT.



- (1) There was no significant difference between the two studied groups regarding patients' age, sex, and smoking index.
- (2) The patients in group I were classified anatomically into 14 pleural cases, 31 parenchymal cases, and five mediastinal cases.
- (3) The patients in group II were classified into 10 pleural cases, 34 parenchymal cases, and six mediastinal cases.
- (4) As regards histopathological diagnosis, in group I there were
  - (a) Among pleural cases, four malignant lesions and seven nonmalignant lesions (either inflammatory or benign tumors).
  - (b) Among parenchymal cases, 21 malignant lesions and seven nonmalignant lesions.
  - (c) Among mediastinal cases, five diagnosed cases were malignant.  
Whereas in group II there were:
    - (d) Among pleural cases, seven malignant lesions and two nonmalignant lesions.
    - (e) Among parenchymal cases, 22 malignant lesions and nine nonmalignant lesions.
    - (f) Among mediastinal cases, four malignant lesions and one nonmalignant lesion.
- (5) In the two studied groups, chest US had the ability to diagnose pleural lesions with a sensitivity of 91.7%, specificity of 89.4%, positive predictive value of 73.3%, negative predictive value of 97.1%, and an accuracy of 90%, whereas in the case of pulmonary lesions they were 90.7, 91.4, 95.1, 84.2, and 91%, respectively, and in mediastinal lesions they were 72.7, 88.7, 44.4, 96.3, and 87%, respectively, indicating that chest US was highly sensitive in diagnosing pleural and parenchymal lesions with comparable specificity in various intrathoracic lesions.
- (6) Chest CT had sensitivity, specificity, positive predictive value, negative predictive value, and accuracy of 100% in pleural, pulmonary, and mediastinal lesions, and thus it was considered the gold standard in the diagnosis of any intrathoracic lesions.
- (7) While on comparing chest US with chest CT, US had sensitivity of 91.7, 90.7, and 72.7% and specificity of 89.4, 91.4, and 88.7% in diagnosing pleural, peripheral pulmonary, and mediastinal lesions, respectively, CT had sensitivity and specificity of 100% in diagnosing pleural, parenchymal, and mediastinal lesions, and thus there was a statistically significant difference between US and CT – with superiority of CT – regarding their sensitivity and specificity in diagnosing pleural, peripheral pulmonary, and mediastinal lesions (Table 1).
- (8) On studying the histopathological results of CNB in the two studied groups, there was a highly significant difference between the percentage of diagnosed and nondiagnosed cases in pleural, parenchymal, or mediastinal lesions in the two groups (Table 2):
  - (a) In group I, only three undiagnosed cases from 14 pleural cases, three undiagnosed from 31 parenchymal cases, and five mediastinal cases were detected.
  - (b) In group II, one undiagnosed case from 10 pleural cases, three undiagnosed cases from 34 parenchymal cases, and one undiagnosed case from six mediastinal cases were detected.
- (9) When comparing US CNB with CT CNB, CT was more diagnostic than US as guidance for pleural biopsies, while in peripheral parenchymal biopsies there was no significant difference between the two groups, but in mediastinal biopsies US was more diagnostic than CT (Table 3).
- (10) On studying complications rate and their risk factors, the present study revealed that pneumothorax and pulmonary hemorrhage were the only complications encountered in this study [there were two cases (4%) of pneumothorax and two cases (4%) of pulmonary hemorrhage in group I, whereas in group II there were three cases (6%) of pneumothorax and three cases (6%) of pulmonary hemorrhage] – that is, the incidence of complications of CT-guided CNB were more.

## Discussion

CT is commonly used for the diagnosis of thoracic lesions as it has the benefit of enhancing resolution and removing superimposition with exquisite depiction of the lesion and its relationship with major vascular structures. But it has the disadvantages of high cost and exposure to ionizing radiation; in addition, it lacks the bedside availability and needs considerable patient cooperation at certain positions and requires intravenous injection of contrast material (with its possible complications) [11].

Transthoracic ultrasound (TUS) permits visualization of these lesions, their structural characterization, and with the aid of color Doppler, the internal echotexture of the lesion can be evaluated allowing precise targeting of central necrosis in large masses [12]. Furthermore, US allows percutaneous-guided biopsies with lower risks compared with the radiological guiding methods (as CT). US has numerous advantages: accessibility (including bedside exams), real-time monitoring, lower costs, no radiation exposure, and shorter biopsy time. In addition, the biopsy route is selected to avoid puncturing aerated lung or great vessels; the tip of the needle and, occasionally, the needle shaft can be monitored throughout the procedure; the

depth of penetration can be determined minimizing the risk of complications and improving safety [13].

**Table 1 Statistical comparison between chest ultrasonography and computed tomography regarding their specificity, sensitivity, and accuracy in detecting pleural, pulmonary, and mediastinal lesions (100 cases)**

Lesions	Chest US	Chest CT	P
Pleural (n = 24 cases)			
Sensitivity %	91.7	100	0.002*
Specificity %	89.4	100	0.001*
Accuracy %	90	100	0.001*
Parenchymal (n = 65 cases)			
Sensitivity %	90.7	100	0.001*
Specificity %	91.4	100	0.002*
Accuracy %	91	100	0.002*
Mediastinal (n = 11 cases)			
Sensitivity %	72.7	100	0.001*
Specificity %	88.7	100	0.001*
Accuracy %	87	100	0.001*

CT, computed tomography; US, ultrasound; \*Significant at  $P \leq 0.05$ .

**Table 2 Patients' distribution according to their final diagnosis in the two studied groups**

Origin of the lesions	US-guided biopsy	CT-guided biopsy	P
Pleural lesions	78.6% (11/14 cases)	90% (9/10 cases)	0.031*
Parenchymal lesions	90.3% (28/31 cases)	91.2% (31/34 cases)	0.809
Mediastinal lesions	100% (5/5 cases)	83.3% (5/6 cases)	0.001*

CT, computed tomography; US, ultrasound; \*Significant at  $P \leq 0.05$ .

**Table 3 The diagnostic outcome of ultrasound-guided biopsy versus computed tomography-guided biopsy in pleural, parenchymal, and mediastinal lesions**

Nature of lesion	Origin of lesion	Histopathology	Group I (n = 50) [n (%)]	Group II (n = 50) (%) [n (%)]	
Malignant	Pleural	Malignant mesothelioma	4 (8)	5 (10)	
		Metastatic pl. malignancy	0 (0)	2 (4)	
	Parenchymal	Adenocarcinoma	9 (18)	7 (14)	
		Bronchoalveolar carcinoma	1 (2)	1 (2)	
		Squamous cell carcinoma	8 (16)	8 (16)	
		Large cell carcinoma	1 (2)	2 (4)	
		Small cell carcinoma	1 (2)	2 (4)	
		Metastatic pul. malignancy	1 (2)	2 (4)	
	Mediastinal	Non-Hodgkin lymphoma	3 (6)	2 (4)	
		Thymic carcinoma	1 (2)	1 (2)	
Neurofibrosarcoma		1 (2)	1 (2)		
Inflammatory	Pleural	Ch. empyema	2 (4)	0 (0)	
		Infected hemothorax	1 (2)	0 (0)	
	Parenchymal	Ch. granulomatous caseating lesion (TB)	1 (2)	2 (4)	
		Necrotizing pneumonia	1 (2)	0 (0)	
		Unresolved pneumonia	4 (8)	6 (12)	
		Ch. lung abscess	1 (2)	0 (0)	
		Progressive massive fibrosis	0 (0)	1 (2)	
		Mediastinal	Ch. granulomatous noncaseating lesion (sarcoidosis)	0 (0)	1 (2)
	Benign	Pleural	Pl. fibroma	3 (6)	1 (2)
Pl. plaque			0 (0)	1 (2)	
Anthracois			1 (2)	0 (0)	

However, there are some limiting factors that prohibit sonographic evaluation of the chest, which are based on physical limitations of the US beam [14].

Thus, in this study, we compared the diagnostic yield of thoracic US with CT-guided core biopsy in diagnosing peripheral intrathoracic lesions. A total of 100 patients with peripheral intrathoracic lesions were selected and divided into two groups (50 patients for each). In group I (US-guided core biopsy), there were 14 pleural cases, 31 peripheral pulmonary cases, and five mediastinal cases. Whereas in group II (CT-guided core biopsy), there were 10 pleural cases, 34 peripheral pulmonary cases, and six mediastinal cases.

In this study, as regards pleural diseases, the sensitivity of US was 91.7 versus 100% of CT, whereas specificity was 89.4% of US compared with 100% of CT.

This was inconsistent with a study conducted by Lichtenstein *et al.* (2004) [15], which reported a diagnostic accuracy 93% of US compared with 100% of CT in diagnosing pleural effusion in 32 patients [16].

However, in a study, Yu *et al.* (1993) [17], comparing US with CT in the assessment of 50 patients with unilateral opaque hemithorax, found that not only did US have a sensitivity of 95.1% for pleural lesions but US also showed pleural and parenchymal diseases that were not identified at CT in six patients. In addition, Chira *et al.* (2012) [14] reported that US (10 cases)

is more sensitive than CT (eight cases) in diagnosing small pleural effusion. This can be explained that in the present study not all pleural cases were of sole pleural pathology, whereas associated parenchymal or mediastinal lesions may be present, which cannot be fully evaluated by US.

On the other hand, Evans and Glesson (2004) [17] proved that CT is superior to US in determining diffuse pleural thickening, and explained that pleura thickening cannot usually be seen by US until at least 1 cm in depth, and that the whole circumference of the pleural surfaces involved including mediastinal pleura cannot be fully assessed by US [17].

Whereas in parenchymal lesions, our results showed that the sensitivity of US was 90.7 versus 100% of CT and the specificity was 91.4 versus 100%, respectively.

This result was in agreement with a study conducted by Lichtenstein *et al.* (2004) [18]. They found, in their study on 65 critically ill patients of alveolar consolidation proven on CT, that US presented 90% sensitivity and 98% specificity, demonstrating that chest US is a reliable diagnostic tool in the accurate detection and location of alveolar consolidation [18].

Whereas Koh *et al.* (2002) [19] reported that US is a valuable tool in the assessment of Pancoast tumor compared with CT as visualization of the extent of the tumor can be limited by using CT because of the orientation of the scan plane, and US is superior in the assessment of any associated pleural or chest wall extension [19].

In mediastinal lesions, our results showed that the sensitivity of US was 72.7 versus 100% of CT and its specificity was 88.7 versus 100% of CT.

This result was in agreement with Wernecke *et al.* (1990) [20] who reported that the diagnostic yield of sonographic examination in the different mediastinal compartments varied from 85% (subcarinal region) to 96% (supra-aortic region) in comparison with 100% of CT, which was used as the reference method [20].

In addition, Hirche *et al.* (2002) [21] stated that the gold standard for evaluation of the mediastinum is represented by thoracic CT, which demonstrates all important structures of this region and supplies information about pathologic changes of the lung hilum and parenchyma. On studying the sonographic examination of the mediastinum, they found limited role of US in accessibility to the mediastinal region; moreover, its predominantly solid structure has limited specificity by US and difficulty in clear definition of the anatomic regions [21].

In contrast, Wernecke and Diederich (1994) [22] were in favor of mediastinal US, and stated that sonography permits visualization of internal architecture of the tumor, which may suggest a specific diagnosis when considered along with the location of the tumor and clinical presentation; in addition, US permits distinction between solid, cystic, calcified, and vascular structures. In the differential diagnosis of solid mediastinal masses, sonography has problems similar to those of CT. Various solid mediastinal tumors show similar morphologic features at sonography and CT, and the diagnosis often requires histologic examination of the mass. Moreover, sonography may play an important role in the assessment of mediastinal lymphadenopathy because the qualitative criterion (echogenicity) it offers can be a more reliable indicator of vital tumor on inflammatory tissue than the quantitative criterion (lymph node size) used with CT [22].

In the present study, US-guided core biopsy was performed in group I (50 cases) and the results showed 11 diagnosed cases from 14 cases of pleural lesions (78.6%), 28 diagnosed cases from 31 parenchymal lesions and all five diagnosed cases (100%) from five mediastinal lesions.

On the other hand, CT-guided-core biopsy was done in group II (50 cases) and the results showed nine diagnosed cases out of 10 cases (90%) of pleural lesions, 31 diagnosed cases out of 34 (91.2%) parenchymal lesions and five diagnosed cases out of six (83.3%) mediastinal lesions.

On comparing the diagnostic yield of US versus CT as guidance for diagnosing pleural lesions, the present study showed statistically significant difference ( $P < 0.05$ ) between US and CT with superiority of CT. This result is in accordance with a study conducted by Sartori and Tombesi (2010) [12], who reported that TUS has some limits and cannot be considered as an alternative to thoracic CT for the study of pleural pathology. They explained that the sonographic waves are hindered by air and bony structures, and as a consequence, TUS does not provide any diagnostic information in the presence of subcutaneous emphysema, and cannot visualize subscapular, paravertebral, and retrosternal lesions. Moreover, CT is superior to TUS for investigating focal and diffuse pleural diseases, as it enables one to evaluate all parts of the pleura, including the mediastinal pleura, and can better delineate the pulmonary and pleural components of a mass. In addition, TUS is strictly operator dependent and only skilled examiners with a lot of experience can obtain good and reliable results [12].



This result is not in agreement with studies conducted by Diacon *et al.* (2004) [23] and Bahr *et al.* (2014) [24], who studied the safety and yield of US-assisted transthoracic biopsy performed by pulmonologists and reported that US as guidance of Tru-cut needle biopsy had diagnostic yield of 85.5% in diagnosing peripheral lesions, suggesting that US assistance might substitute CT guidance for lesions greater than or equal to 20 mm in diameter, irrespective of the presence of a pleural effusion. Moreover, it is far more accessible than CT in many peripheral healthcare facilities, and has a simpler and low-cost diagnostic technique particularly in regions with high asbestos exposure [23,24].

When the diagnostic yield of US-guided biopsy was compared with that of CT-guided biopsy for parenchymal lesions, the present study revealed no significant difference between US and CT as guidance for peripheral pulmonary lesions. This result is consistent with a study conducted by Blank (2011) [25], who reported that speed is the true advantage of the US-guided approach over transthoracic biopsy. The efficacy of US (the diagnostic yield exceeds 90%) is similar to that of the other imaging techniques – CT in first place – but the time that the needle spends in the lesion is far less with US, with a gain in tolerability and less complications. Moreover, US permits identifying eventual postprocedural complications such as pneumothorax [25].

In this study, the diagnostic yield of the US-guided biopsy was compared with the CT-guided biopsy for mediastinal lesions, and it was reported that US was superior to CT as guidance for mediastinal lesions. This result is in accordance with Liao *et al.* (2013) [3], who documented that US is as effective as CT for guidance of transthoracic biopsies of mediastinal tumors and offers a number of advantages. Real-time US imaging allows for dynamic evaluation of vessels and localization of target lesions that move during respiration [3].

On studying the complications of either US (group I) or CT (group II)-guided biopsy, pneumothorax and pulmonary hemorrhage with hemoptysis were the only complications encountered in this study, as there were in group I only two (4%) cases of pneumothorax and two (4%) cases of pulmonary hemorrhage, and in group II there were three (6%) cases of pneumothorax and three (6%) cases of pulmonary hemorrhage.

In this study; the pneumothorax rate for US-assisted CNB (4%) was comparable with the that of previous studies by Diacon *et al.* (2004) [23] and Chira *et al.* (2012) [14], who observed a rate of 4% for US-assisted CNB especially when there was a wall contact of the tumoral masses and large sizes of lesions greater than

2.8 cm, and they concluded that this maneuver is safe in the hands of pulmonologists. Moreover, Blank (2011) [25] added that US permits identifying eventual postprocedural pneumothorax with diagnostic yield, in expert hands, exceeding 90% [25].

In this study, the pneumothorax incidence for CT-guided CNB (6%) was lower than that of most studies such as those conducted by Anderson *et al.* (2003) [26], Montaudon *et al.* (2004) [27], and Gupta *et al.* (2005) [28], who reported the incidence of pneumothorax following lung biopsy to be as high as 12–69% and that of chest tube placement as 0.5–38% despite advanced techniques. The lower incidence of pneumothorax in our work was due to good selection of cases to be abutted to parietal pleura with no intervening aerated lung tissue.

In the present study, the incidence of pneumothorax following US-guided CNB (4%) was lower than that following CT-guided CNB (6%). This result coincided with other studies such as that of Sheth *et al.* (1999) [13], Geraghty *et al.* (2003) [29], and Chira *et al.* (2012) [14], who reported that pneumothorax incidence was 17–26.6% in patients guided by CT scan while the percentage was less (1–7%) when guided by US considering that the procedure was performed correctly and without any intervening aerated lung tissue. They explained that real-time US imaging allows for monitoring the tip of the needle throughout the procedure and fine adjustments can be made quickly and precisely especially for biopsy of small thoracic lesions [13,14,29].

As regards pulmonary hemorrhage and hemoptysis, their incidence in this study (4% in US-guided CNB and 6% in CT-guided CNB) coincided with the incidence of hemorrhage as a general either in US-guided or CT-guided CNB, which was 1–27%, and this incidence was lower than pneumothorax incidence as reported in most of the literature [30–33]. This may be due to the fact that pneumothorax is easier to identify in chest radiographs and its obvious symptoms are possible to attract notice. By contrast, mild hemorrhage is difficult to identify in chest radiographs [30–33].

## Conclusion

From this study, it was concluded that:

- (1) Both US and CT are efficient tools in the diagnosis of any peripheral intrathoracic lesions provided that the lesions are in contact with the chest wall.
- (2) As guidance for CNB, CT and US have comparable diagnostic accuracy but chest US offers numerous advantages as accessibility (including bedside

examinations), real-time monitoring, lower costs, no radiation exposure, and shorter biopsy time with fewer complications than does CT.

Transthoracic CNB either under US or CT was very efficient, safe, and less invasive diagnostic tool for detecting histopathological diagnosis avoiding unnecessary surgical procedures.

#### Financial support and sponsorship

Nil.

#### Conflicts of interest

There are no conflicts of interest.

#### References

- Gleeson FV. Imaging in chest diseases. *Medicine (Baltimore)* 2008; **36**:132–141.
- Shah A, Desai SR. Imaging in chest diseases. *Medicine (Baltimore)* 2012; **40**:177–185.
- Liao WCh, Tu Ch-Y, Shih Ch-M, Chen Ch-H, Chen H-J, Wu-Huel H. Ultrasound diagnosis of chest diseases. *Intech* 2013; **3**:84–95.
- Hew M, Heinze S. Chest ultrasound in practice: a review of utility in the clinical setting. *Intern Med J* 2012; **42**:856–865.
- Manhire A, Charig M, Clelland C, Gleeson F, Miller R, Moss H, *et al.* Guidelines for radiologically guided lung biopsy. *Thorax* 2003; **58**: 920–936.
- Morvay Z, Szabó E, Tiszlavicz L, Furák J, Tróján I, Palkó A. Thoracic core needle biopsy using ultrasound guidance. *Ultrasound Q* 2001; **17**: 113–121.
- Khankana AA, Al-Muaikeelb M. Image-guided percutaneous transthoracic biopsy in lung cancer – emphasis on CT-guided technique. *J Infect Public Health* 2012; **5**:S22–S30.
- Wu CC, Maher MM, Shepard JA. CT-guided percutaneous needle biopsy of the chest: preprocedural evaluation and technique. *Am J Roentgenol* 2011; **196**:W511–W514.
- Feuerbach S, Schreyer A, Schlottmann K. Standards in radiographically guided biopsies – indications, techniques and complications. *Radiologie Up2date* 2003; **3**:207–223.
- Lourenço R, Camacho R, Barata MJ, Canário D, Gaspar A, Cyrne C. CT-guided percutaneous transthoracic biopsy in the evaluation of undetermined pulmonary lesions. *Rev Port Pneumol* 2006; **12**:503–524.
- Patz EF Jr. Imaging bronchogenic carcinoma. *Chest* 2000; **117**(Suppl 1): 90S–95S.
- Sartori S, Tombesi P. Emerging roles for transthoracic ultrasonography in pulmonary diseases. *World J Radiol* 2010; **2**:203–214.
- Sheth S, Hamper UM, Stanley DB, Wheeler JH, Smith PA. US guidance for thoracic biopsy: a valuable alternative to CT. *Radiology* 1999; **210**: 721–726.
- Chira R, Chira A, Mircea PA. Intrathoracic tumors in contact with the chest wall – ultrasonographic and computed tomography comparative evaluation. *Med Ultrason* 2012; **14**:115–119.
- Lichtenstein D, Goldstein I, Mourgeon E, Cluzel P, Grenier P, Rouby JJ. Comparative diagnostic performances of auscultation, chest radiography, and lung ultrasonography in acute respiratory distress syndrome. *Anesthesiology* 2004; **100**:9–15.
- Yu CJ, Yang PC, Wu HD, Chang DB, Kuo SH, Luh KT. Ultrasound study in unilateral hemithorax opacification. Image comparison with computed tomography. *Am Rev Respir Dis* 1993; **147**:430–434.
- Evans AL, Gleeson FV. Radiology in pleural disease: state of the art. *Respirology* 2004; **9**:300–312.
- Lichtenstein DA, Lascols N, Mezière G, Gepner A. Ultrasound diagnosis of alveolar consolidation in the critically ill. *Intensive Care Med* 2004; **30**:276–281.
- Koh DM, Burke S, Davies N, Padley SP. Transthoracic US of the chest: clinical uses and applications. *Radiographics* 2002; **22**:e1.
- Wernecke K, Vassallo P, Pötter R, Lückener HG, Peters PE. Mediastinal tumors: sensitivity of detection with sonography compared with CT and radiography. *Radiology* 1990; **175**:137–143.
- Hirche TO, Wagner TO, Dietrich CF. Mediastinal ultrasound: technique and possible applications. *Med Klin (Munich)* 2002; **97**:472–479.
- Wernecke K, Diederich S. Sonographic features of mediastinal tumors. *Am J Roentgenol* 1994; **163**:1357–1364.
- Diacon AH, Schuurmans MM, Theron J, Schubert PT, Wright CA, Bolliger CT. Safety and yield of ultrasound-assisted transthoracic biopsy performed by pulmonologists. *Respiration* 2004; **71**:519–522.
- Bahr HM, Shafey MH, Hantera MS, Abo-Elmagd G, El-Batsh AH. Ultrasound guided needle pleural biopsy in patients with undiagnosed pleural effusion. *Egypt J Chest Dis Tuberc* 2014; **63**:113–118.
- Blank W: Interventional chest sonography. In *Chest sonography*. Edited by Mathis G. Springer-Verlag; 2011:187–209.
- Anderson JM, Murchison J, Patel D. CT-guided lung biopsy: factors influencing diagnostic yield and complication rate. *Clin Radiol* 2003; **58**:791–797.
- Montaudon M, Latrabe V, Pariente A, Corneloup O, Begueret H, Laurent F. Factors influencing accuracy of CT-guided percutaneous biopsies of pulmonary lesions. *Eur Radiol* 2004; **14**:1234–1240.
- Gupta S, Krishnamurthy S, Broemeling LD, Morello FA Jr, Wallace MJ, Ahrar K, *et al.* Small ( $\leq 2$  cm) subpleural pulmonary lesions: short-versus long-needle-path CT-guided biopsy-comparison of diagnostic yields and complications. *Radiology* 2005; **234**:631–637.
- Geraghty PR, Kee ST, McFarlane G, Razavi MK, Sze DY, Dake MD. CT-guided transthoracic needle aspiration biopsy of pulmonary nodules: needle size and pneumothorax rate. *Radiology* 2003; **229**:475–481.
- Yildirim E, Kirbas I, Harman A, Ozyer U, Tore HG, Aytekin C, *et al.* CT-guided cutting needle lung biopsy using modified coaxial technique: factors effecting risk of complications. *Eur J Radiol* 2009; **70**:57–60.
- Wu CC, Maher MM, Shepard JA. Complications of CT-guided percutaneous needle biopsy of the chest: prevention and management. *Am J Roentgenol* 2011; **196**:W678–W682.
- Cao BS, Wu JH, Li XL, Deng J, Liao GQ. Sonographically guided transthoracic biopsy of peripheral lung and mediastinal lesions: role of contrast-enhanced sonography. *J Ultrasound Med* 2011; **30**:1479–1490.
- Wiener RS, Schwartz LM, Woloshin S, Welch HG. Population-based risk for complications after transthoracic needle lung biopsy of a pulmonary nodule: an analysis of discharge records. *Ann Intern Med* 2011; **155**: 137–144.