

Organizing pneumonia causing severe respiratory failure as a complication of interferon- α therapy

Maged Hassan, Hatem Essam

Chronic hepatitis C infection is highly prevalent in Egypt. Pegylated interferon- α (in addition to ribavirin) is the standard medication and it is increasingly being used. Despite being very uncommon, interferon therapy has been associated with a plethora of pleuropulmonary complications ranging from mild asthma exacerbation to acute respiratory distress syndrome (ARDS) and death. This is a report of a case of organizing pneumonia occurring in the course of interferon therapy that has been complicated with severe respiratory failure. The pulmonary lesions have miraculously resolved after 10 days of corticosteroid therapy. *Egypt J Broncho* 2016 10:73–75

Introduction

Egypt is one of the most prevalent countries in the world in hepatitis C virus (HCV) infection. The overall prevalence of HCV antibody in the general population ranges between 15 and 20% [1]. The standard treatment of HCV infection is a combination of pegylated interferon- α (peg-IFN) and ribavirin [2]. This combination therapy is invariably associated with cough that is usually mild [3]. Other recognized side effects include myalgia, fatigue, gastrointestinal disturbances, psychiatric disorders, and hematological abnormalities [3]. Although ribavirin is recognized as the responsible cause of cough and dyspnea, there are no documented cases of pathologic pulmonary toxicity due to ribavirin therapy alone [4]. Pulmonary complications, however, have been rarely reported during the course of IFN therapy both for HCV and malignancy [2–6].

Case history

A 44-year-old man who had a medical history of HCV infection sought medical advice for cough and progressive exertional dyspnea of 3 weeks' duration. He was prescribed oral antibiotics for 5 days. After severe worsening of the condition, the patient was admitted to our institution. The patient's dyspnea started with exertion and progressively increased over 3 weeks to be present at rest. His cough was productive with little mucoid sputum, and it increased progressively such that the patient could not eat, drink, or sleep. The patient denied having fever, sweating, chest pain, or hemoptysis. He also denied traveling recently, having contacts with any sick person, or smoking. He has been on weekly subcutaneous peg-IFN and daily oral ribavirin for HCV for 24 weeks. On examination,

© 2016 Egyptian Journal of Bronchology.

Egyptian Journal of Bronchology 2016 10:73–75

Keywords: drug-induced respiratory disease, interferon- α , interstitial pneumonitis, organizing pneumonia, hepatitis C

Department of Chest Diseases, Faculty of Medicine, Alexandria University, Alexandria, Egypt

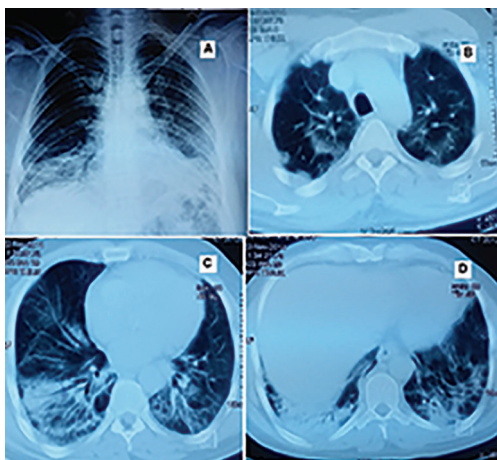
Correspondence to Maged Hassan, MSc, Chest Diseases Department, Faculty of Medicine, Alexandria University, Khartoum Square, 21521 Azarita, Alexandria, Egypt
Tel: +20 122 332 7822; fax: +203-3352709;
e-mail: magedhmf@gmail.com

Received 16 May 2015 **Accepted** 25 May 2015

the patient was cyanosed and in respiratory distress. There was no lower limb edema, clubbing, or neck vein congestion. Chest examination revealed bilateral basal crackles. A chest radiograph revealed bilateral lower zonal consolidation (Fig. 1a). Computed tomography (CT) of the chest was performed, which showed bilateral airspace consolidation with patchy ground glass opacities affecting all lung lobes (Fig. 1b–d). Some of the consolidated areas showed the reverse halo pattern (Fig. 1c). Blood gasometry confirmed severe respiratory failure (PaO₂ 62 mmHg on FiO₂ 60%). White blood cell count was normal and C-reactive protein was mildly elevated. Sputum culture was negative for bacteria and fungi as was the smear for acid fast bacilli. Flexible bronchoscopy was not performed because of the perceived risk for fatal hypoxemia from the procedure. Peg-IFN and ribavirin were stopped and the patient was started on dexamethasone (dose equivalent to 60 mg of prednisone) and azithromycin. Organizing or infectious pneumonia were the probable diagnoses. The patient's symptoms dramatically improved, and he could maintain a PaO₂ of 60 mmHg without oxygen 1 week after initiation of therapy (hypoxic index improved from 100 at admission to 285). He was discharged from the hospital 5 days later when the arterial saturation exceeded 92% on ambient air and a follow-up chest radiograph revealed a near-total resolution of the opacities (Fig. 2a). A dose of 40 mg of oral prednisone was tapered to 15 mg over 6 weeks when the patient returned for follow-up. A

This is an open access article distributed under the terms of the Creative Commons Attribution-NonCommercial-ShareAlike 3.0 License, which allows others to remix, tweak, and build upon the work non-commercially, as long as the author is credited and the new creations are licensed under the identical terms.

Fig. 1



(a) Chest radiograph shows bilateral lower zonal patchy infiltration. (b) Upper lobar patches bilaterally in chest computed tomography (CT). (c) Reverse halo sign (atoll sign) in the right lower lobe. (d) Lower lobar patches, denser on the right side.

new CT only revealed minimal fibrosis around the fissures (Fig. 2b). Given the tremendous clinical and radiological improvement following steroids, the suggestive radiological features, and the lack of evidence of an infectious etiology, the diagnosis was 'organizing pneumonia (OP) complicating IFN therapy'.

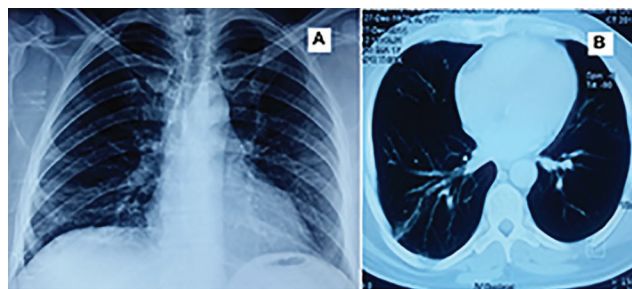
Discussion

Interferon has been associated with various side effects, including fatigue, flu-like symptoms, arthralgia, myalgia, gastrointestinal symptoms, and depression. Among rare side effects of IFN are arrhythmias, cardiomyopathy, pancreatitis, and pulmonary toxicity [2]. The drug-induced respiratory disease database 'Pneumotox' lists nine disease categories of pleuropulmonary nature that have been directly linked to IFN therapy [7]: interstitial lung disease, sarcoid-like thoracic disease, lymphadenopathy, nagging cough, OP, ARDS, pleural effusion, pulmonary arterial hypertension, and asthma exacerbation [7].

The first report of pulmonary toxicity following IFN therapy dates back to 1987 when a patient with advanced renal cell carcinoma developed pulmonary sarcoidosis during IFN therapy [5]. The first conclusive evidence of a causal relation was provided by Kamisako *et al.* [6], who retrieved a lymphocyte-rich bronchoalveolar lavage from a patient who developed interstitial pneumonitis when receiving IFN for HCV infection. These lymphocytes showed sensitization to IFN- α .

All proposed mechanisms to explain pulmonary damage precipitated by IFN have centered around

Fig. 2



(a) Follow-up chest radiograph after 2 weeks shows clearing of previously noted infiltrates. (b) Follow-up chest computed tomography (CT) after 1 month shows minimal residual fibrosis in the right lower lobe.

its known capacity for immunomodulation [4]. This involves inhibition of suppressor T cells, enhancement of cytotoxic T cells, induction of proinflammatory cytokines, and exaggerated release of fibrinogenic cytokines leading to lung fibrosis [8].

The onset of IFN-induced lung disease is heralded by the development of dyspnea or cough, which is usually dry and sometimes difficult to differentiate from the flu-like symptoms of IFN [2]. Symptoms have been reported to develop between 3 weeks and 10 months after initiation of therapy [4]. Both regular and peg-IFN- α have been culprits [2]. The most common form of toxicity is interstitial pneumonitis. OP has been reported less commonly.

The therapeutic options for IFN-induced pulmonary toxicity have been either stopping the offending drug only or adding systemic steroids [4]. Except for rare occasions, this strategy has been successful in reversing the disease, or at least to halt its progression [4].

OP is a distinct clinicopathological entity characterized by the filling of bronchioles, alveolar ducts, and alveoli with granulation tissue [9]. It typically presents with a few weeks' history of productive cough of small amount of sputum, exertional dyspnea, and low-grade fever [9]. The most common CT findings are bilateral patchy areas of air-space consolidation with subpleural or peribronchovascular predominance [10]. The reverse halo sign (central ground-glass opacity surrounded by more dense air-space consolidation of crescentic and ring shapes), although less common, appears to be relatively specific to OP [10]. Many drugs have been reported to cause OP, including IFN- α [9].

In the reported case, the clinical course has been progressive, reaching severe respiratory failure – a feature not typical for OP. Drug-induced OP has been known to be resistant to steroid treatment [9], which was also different from the course of our case. Steroids were tapered over a 6-month-period from 60 mg prednisone,

without any sequelae for the patient and without flare in HCV infection. To our knowledge, this is the first case report of OP following IFN to take this severe course and to show such marvelous improvement.

IFN-induced lung toxicity is not common but serious, and can lead to irreversible damage and death if unrecognized. Steroids have been pivotal in managing cases with acute course when withholding the drug may be sufficient in chronic cases.

Financial support and sponsorship

Nil.

Conflicts of interest

There are no conflicts of interest.

References

- 1 Frank C, Mohamed MK, Strickland GT, Lavanchy D, Arthur RR, Magder LS, *et al.* The role of parenteral antischistosomal therapy in the spread of hepatitis C virus in Egypt. *Lancet* 2000; **355**:887–891.
- 2 Slavenburg S, Heijdra YF, Drenth JP. Pneumonitis as a consequence of (peg)interferon-ribavirin combination therapy for hepatitis C: a review of the literature. *Dig Dis Sci* 2010; **55**:579–585.
- 3 Atug O, Akin H, Alahdab YO, Ceyhan B, Tozun N, Ozdogan O. Interstitial pneumonitis associated with pegylated interferon-alpha 2a and ribavirin for chronic hepatitis C infection: a case report. *Cases J* 2009; **2**:6464.
- 4 Midturi J, Sierra-Hoffman M, Hurley D, Winn R, Beissner R, Carpenter J. Spectrum of pulmonary toxicity associated with the use of interferon therapy for hepatitis C: case report and review of the literature. *Clin Infect Dis* 2004;**39**:1724–1729.
- 5 Abdi EA, Nguyen GK, Ludwig RN, Dickout WJ. Pulmonary sarcoidosis following interferon therapy for advanced renal cell carcinoma. *Cancer* 1987; **59**:896–900.
- 6 Kamisako T, Adachi Y, Chihara J, Yamamoto T. Interstitial pneumonitis and interferon-alfa. *BMJ* 1993; **306**:896.
- 7 Camus P. Interferon alpha/beta induced lung disease [Internet]. Pneumotox. Available at: <http://www.pneumotox.com/drug/view/161/interferon-alpha-beta/> [Last accessed on 2015 May 14].
- 8 Borden EC, Parkinson D. A perspective on the clinical effectiveness and tolerance of interferon-alpha. *Semin Oncol* 1998; **25** (Suppl 1): 3–8.
- 9 Al-Ghanem S, Al-Jahdali H, Bamefleh H, Khan AN. Bronchiolitis obliterans organizing pneumonia: pathogenesis, clinical features, imaging and therapy review. *Ann Thorac Med* 2008; **3**:67-75.
- 10 Kim SJ, Lee KS, Ryu YH, Yoon YC, Choe KO, Kim TS, Sung KJ. Reversed halo sign on high-resolution CT of cryptogenic organizing pneumonia: diagnostic implications. *Am J Roentgenol* 2003; **180**: 1251–1254.