

# Granulomatosis with polyangiitis: Rheumatoid arthritis overlap syndrome: A case report

Ashraf E. Sileem, Ahmed M. Said

Antineutrophil cytoplasm antibody (ANCA)-associated vasculitis (AAV) may rarely be associated with other immune-mediated diseases. Knowledge of these overlap syndromes is important in early recognition of potential complications and differences in clinical courses and management pathways. In this paper we describe the case of a male Egyptian patient, 52 years old, with hypertension and rheumatoid arthritis on disease-modifying antirheumatic drugs, with a recent history of ocular and renal manifestations suggesting vasculitis, who presented to our Emergency Department with acute interstitial pneumonitis, which was successfully treated with high-dose steroids. His clinical course had deteriorated because of self-stoppage of the maintenance dose of steroid and appearance of bilateral nodular infiltrates in the lungs on the chest radiographs. His cytoplasmic c-ANCA autoantibodies were positive, in addition to the histopathological examination of open lung biopsy, which was consistent with granulomatosis with polyangiitis. He was successfully treated with high-dose steroids and cyclophosphamide. We reported a new case of granulomatosis with polyangiitis developing during

## Introduction

Wegener's granulomatosis (WG) is a multisystem disease characterized by a necrotizing granulomatous vasculitis affecting predominantly the lower and upper respiratory tract, lungs, and kidneys. The prevalence of the disease is about three persons per 100 000 people, equally in both sexes [1].

The German pathologist Friedrich Wegener first described the disease in 1936. In 1954, Godman and Churg more fully delineated the disease and established the three main clinical criteria of WG (vasculitis, glomerulonephritis, respiratory tract involvement). Clinical manifestations and organ involvement of the disease vary widely [2].

Clinically, antineutrophil cytoplasm antibody (ANCA)-associated vasculitis (AAV) may rarely be associated with other immune-mediated diseases. Those that have been well recognized include antglomerular basement membrane disease [3,4], scleroderma [5], systemic lupus erythematosus [6], and membranous glomerulonephritis [7,8]. Knowledge of these overlap syndromes is important in early recognition of potential complications and differences in clinical courses and management pathways.

Draibe and Salama [9] noticed the development of AAV in a group of patients with rheumatoid arthritis (RA), where there was a delay in presentation with vasculitic symptoms following the diagnosis of RA.

adalimumab therapy for rheumatoid arthritis. This clinical observation must be considered in all patients treated with anti-tumor necrosis factor. On the basis of the previously published cases of AAV associated with rheumatoid arthritis as well as our case, the suggestion of a rare form of an AAV autoimmune overlap should be recognized and investigated for rapid initiation of appropriate management.

*Egypt J Bronchol* 2017 11:56–61

© 2017 Egyptian Journal of Bronchology

**Egyptian Journal of Bronchology** 2017 11:56–61

**Keywords:** adalimumab, overlap syndrome, rheumatoid arthritis, Wegener's granulomatosis

Chest Department, Zagazig University, Zagazig, Egypt

Correspondence to Ashraf E. Sileem, MD, Department of Chest, Zagazig University Hospitals, Al-Salam Sector, Cardiothoracic Building, Zagazig, Sharkia, Egypt; Tel: +201273258514; e-mail: sileem.ashraf@yahoo.com

**Received** 3 September 2015 **Accepted** 29 September 2015

## Case presentation

We present the case of a male Egyptian patient, aged 52 years, married and with two children, who was a known hypertensive diagnosed 6 years ago and who was on oral candesartan 8 mg once daily. He was diagnosed as a case of RA 5 years ago on the basis of seropositive RA [rheumatoid factor (90.7 IU/ml) and anticitrullinated protein antibody (58 IU/ml)], swelling and tenderness of his small joints in both hands for more than 2 months (the metacarpophalangeal and proximal interphalangeal joints) as shown in Fig. 1, and abnormal acute-phase reactants [C-reactive protein (CRP) and erythrocyte sedimentation rate (ESR)] during the diagnosis. His medication list included methylprednisolone 5 mg, methotrexate, and disease-modifying antirheumatic drugs (leflunomide 20 mg, adalimumab injection 40 mg every other week), omega 3, folic acid, and esomeprazole 20 mg.

On 21 May 2014, the patient presented to the ophthalmologist with defective vision in the right eye with appearance of red eye. The ophthalmology report revealed nodular scleritis, anterior uveitis, and papilledema. Fluorescein angiography and optical

This is an open access article distributed under the terms of the Creative Commons Attribution-NonCommercial-ShareAlike 3.0 License, which allows others to remix, tweak, and build upon the work noncommercially, as long as the author is credited and the new creations are licensed under the identical terms.

coherence tomography revealed leakage at the macula and optic nerve head, as shown in Fig. 2.

Methylprednisolone 100 mg/day, topical steroid, and cycloplegic mydriatics were prescribed. The steroid was tapered to 20 mg within 2 weeks with reasonable response as regards eye redness and vision improvement.

After 2 weeks, he relapsed with defective vision, with optical coherence tomography evidence of cystoid macular edema, and attack of hematuria and decline in renal function (creatinine was 3.2 mg/dl with active urinary sediment). He was injected with intravitreal triamcinolone acetonide with recommendation to continue systemic steroid at 20 mg/day for 1 month. He showed improvement as regards his ocular and urinary complaints as well as renal function, and urine analysis revealed normal levels.

On 26 July 2014, he presented at the ER with fever, dry cough, shortness of breath, and respiratory distress. His blood pressure was 140/100, pulse was 120 beats/min, temperature was 38°C, respiratory rate was 32 breaths/

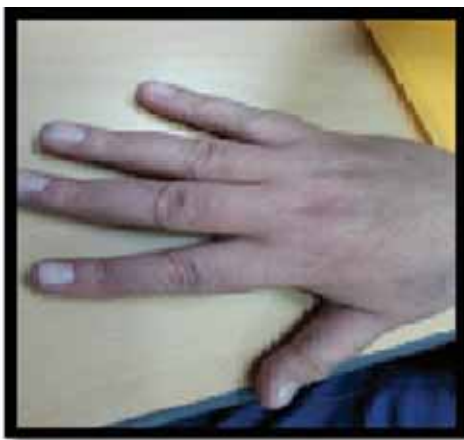min, and O<sub>2</sub> saturation was 87%. On local physical examination, there was diminished vesicular breath-sound intensity and bilateral fine late inspiratory crackles. Chest radiography revealed bilateral micronodular infiltrates with predominance of left upper and middle lung zones.

He was admitted to the ICU, with a provisional diagnosis of atypical pneumonia, with referral to a chest physician.

His arterial blood gases, on 5 l/min humidified oxygen face mask, were as follows: pH 7.5, PaCO<sub>2</sub> 22.9, PaO<sub>2</sub> 56.4, HCO<sub>3</sub> 21.6, BE -3.3, O<sub>2</sub> saturation 89%. d-dimer was negative, CRP was high (270 mg/l), complete blood count was normal, blood urea was 68 mg/dl, serum creatinine was 3.09 mg/dl, and uric acid was 9.1 mg/dl, with normal serum electrolytes.

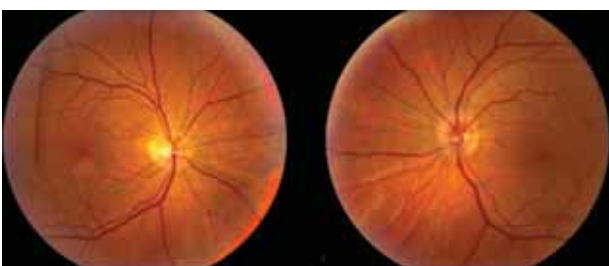
High-resolution chest CT without contrast revealed evidence of interstitial thickening involving scattered areas of both lung fields with preserved lung volumes; upper and mid zones were prominently involved; the interstitial prominence was more centrally located; there were mild reticular opacities in both apices and patchy areas of ground-glass haziness in the perihilar region and upper lung zones bilaterally. Bilateral pleural reactions were also noted, as shown in Fig. 3.

**Figure 1**



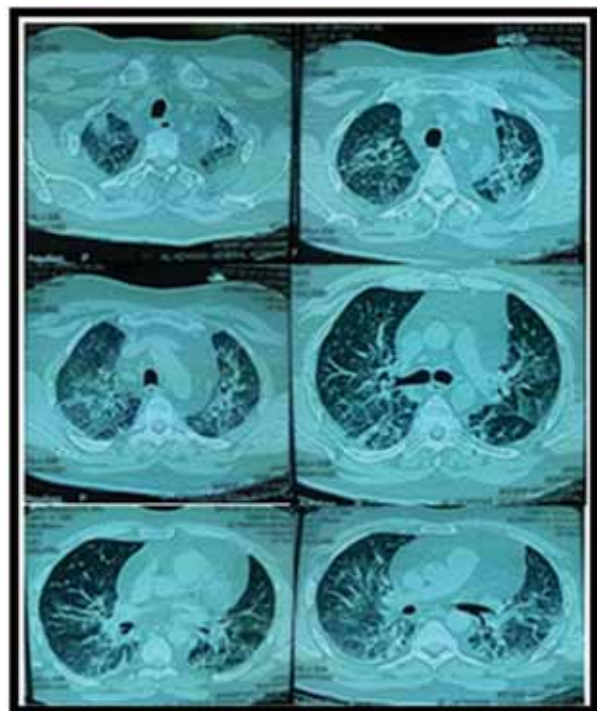
Boggy swelling in proximal interphalangeal and metacarpophalangeal joints.

**Figure 2**



Optical coherence tomography (OCT) revealed leakage at the macula and optic nerve head.

**Figure 3**



High-resolution chest computed tomography (CT) without contrast.

He was diagnosed as a case of acute interstitial pneumonitis with respiratory failure type I in case of RA. Methotrexate was held and treatment started in the form of oxygen therapy, methylprednisolone 250 mg intravenously twice daily, clarithromycin 500 mg oral twice daily, and *N*-acetylcysteine 600 mg twice daily.

Previous medications continued for 5 days, with daily improvement of patient's general condition and laboratory investigations; especially serum creatinine and CRP returned to normal values. The patient was discharged on 60 mg prednisolone and pantoprazole 40 mg, clarithromycin 500 mg tablet twice daily for 7 days, with weekly follow-up.

The patient was asymptomatic during the weekly visits for 1 month, and the steroid dose was gradually tapered the next month to 40 mg daily.

High-resolution chest CT without contrast after 6 weeks revealed significant reduction in the interstitial thickening and ground-glass haziness, no

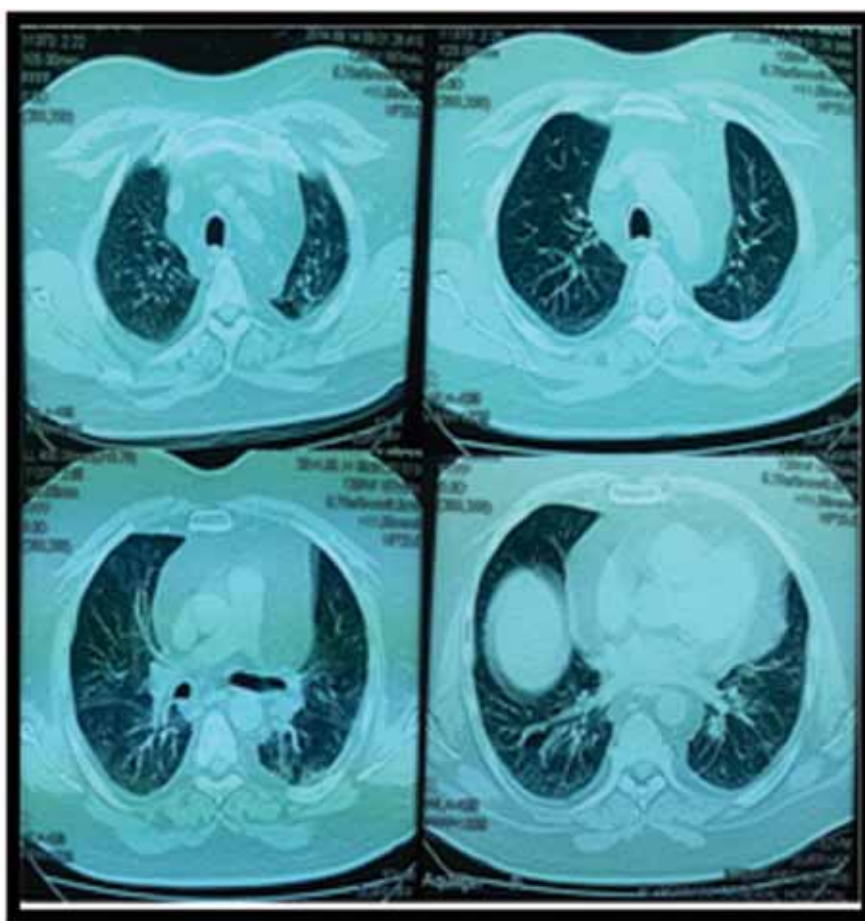
pleural effusion, and no pulmonary fibrosis or nodularity, as shown in Fig. 4.

The patient was advised to continue on 30 mg/day and oral *N*-acetylcysteine 600 mg twice daily for 1 month. Thereafter, the steroid was tapered and the patient was advised to consult a rheumatologist. The steroid was tapered to 10 mg/day and stopped abruptly by the patient after 2 months.

On 10 December 2014, the patient presented at the chest clinic complaining of dry infrequent cough, low-grade fever, nasal dryness, loss of appetite, and fatigue; his clinical examination was unremarkable apart from flushed face. He had sinus tachycardia (114 beats/min), O<sub>2</sub> saturation 95%, and respiratory rate 18 breaths/min.

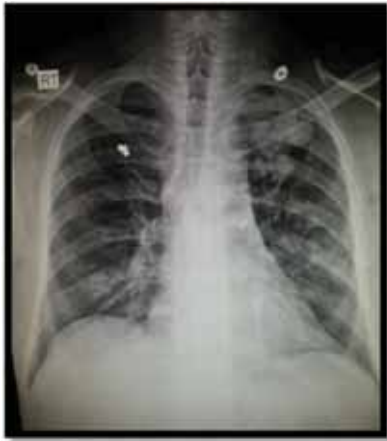Chest radiography revealed bilateral pulmonary nodules; they were multiple on the left upper and mid lung zone, and solitary on the right lower lung zone, as shown in Fig. 5.

Figure 4



High-resolution chest computed tomography (CT) without contrast after 6 weeks on 40 mg prednisolone.

Figure 5



Chest radiography revealing bilateral pulmonary nodules.

The patient was admitted to a regular ward, and systemic steroids were resumed in the form of methylprednisolone 125 mg intravenously three times daily, ciprofloxacin 400 mg intravenously twice daily, and clarithromycin 500 mg twice daily orally. His CRP was 303 mg/l and ESR was 98 mm in the first hour; he had thrombocytosis; sputum gram stain revealed gram-positive cocci in pairs and pus cells, negative for acid fast bacilli for 3 successive days; serum creatinine was 1.3 mg/dl, uric acid was 6.2 mg/dl, and rheumatoid factor was positive (23.7 IU/ml).

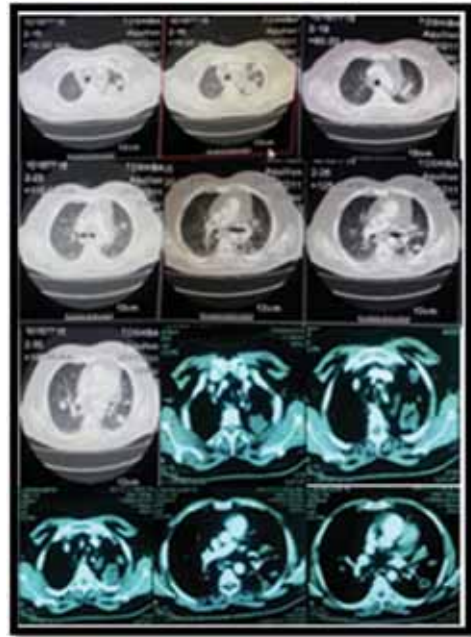
Chest CT with contrast performed on 11 December 2014 revealed multiple variably sized mostly pleural-based bilaterally nonsignificantly enhancing soft tissue nodules with no evidence of calcifications. The largest nodule was located more posteriorly in the left upper lobe with small cavitations seen within. Another small nodule was noted on the right side of the posterior mediastinum, as shown in Fig. 6.

Repeat CRP after 4 days of the above regimen markedly decreased to 10 mg/l. Patient symptoms also subsided, and radiological shadows remained unchanged. ENT consultation revealed that the upper respiratory tract was free.

As regards the patient's medical history starting with ocular manifestations, there were two different radiological pulmonary presentations: interstitial pneumonitis and cavitating pulmonary nodules. In addition, there was renal involvement at first admission along with nonspecific constitutional symptoms. The suspicion of vasculitides was raised as a possibility, and hence c-ANCA were asked for, with strong positive results (1/320).

The patient was referred to a cardiothoracic surgeon for open lung biopsy, which was sent for histopathological

Figure 6



Chest computed tomography (CT) with contrast revealing multiple variably sized mostly pleural-based bilaterally nonsignificantly enhancing soft tissue nodules.

examination. The examination revealed large areas of coagulative and focally liquefactive necrosis, with surrounding aggregates of histocytes and multiple granulomas. Focal vasculitis was also noted. No evidence of malignancy was seen. GMS stain for fungus and ZN stain for acid fast bacilli were negative, as shown in Fig. 7

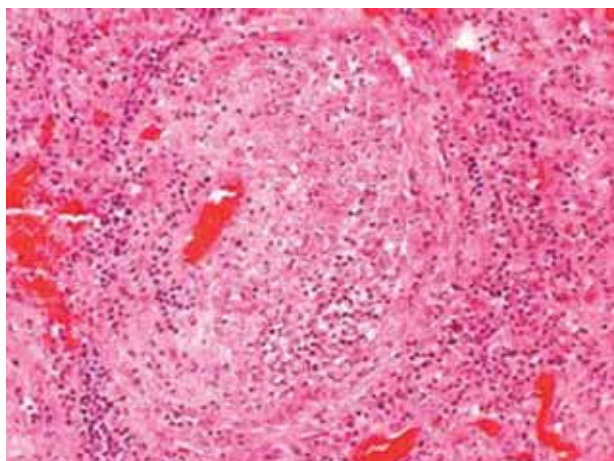
Treatment with methylprednisolone 60 mg daily and cyclophosphamide 750 mg monthly was started, with subsequent steroid tapering. At 3-month follow-up the patient presented a good clinical response with complete radiological improvement, as shown in Fig. 8.

### Case discussion

The patient was diagnosed according to the American College of Rheumatology/European League Against Rheumatism Classification Criteria for RA (2010) as having seropositive RA (score 8) [10].

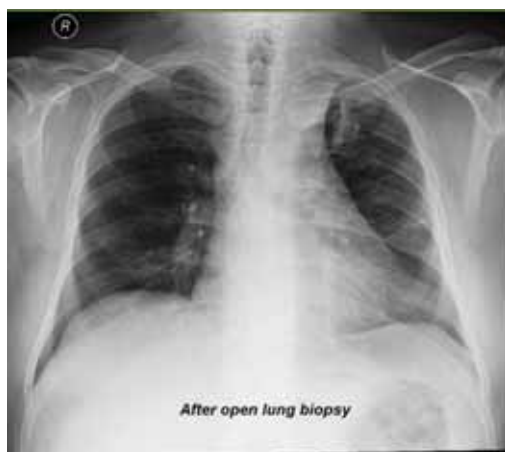This patient's progressive multisystem complaints over a period of months – ocular symptoms, renal dysfunction, various pulmonary manifestations, along with elevated ESR, CRP, rheumatoid factor, and c-ANCA – strongly supported the diagnosis of systemic vasculitis. The differential diagnosis included WG, microscopic polyangiitis, Churg–Strauss syndrome, and antglomerular basement membrane or Goodpasture syndrome (more common in men), as well as systemic

Figure 7



Histopathological examination of a resected specimen from the left upper lobe lung nodules.

Figure 8



Postoperative plain chest radiography.

lupus erythematosus and, less likely, Behçet's disease and RA [11].

On the basis of the ocular examination findings, abnormal chest radiography, abnormal urinary sediment, c-ANCA positivity, and histopathological picture, the diagnosis of granulomatosis with polyangiitis (GPA) (formerly WG) was established according to the American College of Rheumatology (ACR) 1990 and revised Chapel Hill Consensus Conference (CHCC) criteria 2012 [12,13].

The first manifestation in our patient was ocular involvement, which is a rare initial presentation of WG in 8–16% of cases [14].

Usually, renal involvement is severe and the leading cause of mortality in WG [15], but our patient's renal function was only mildly affected.

Typical radiological presentations of lung involvement in WG are multiple, bilateral, nodular infiltrations, with or without cavities. According to some data, in 20–50% of patients it is manifested with pleural effusion. Atypical presentations are interstitial lung disease, hilar mass, or pneumothorax [16,17].

The first pulmonary presentations of our patient with WG at the ICU were acute interstitial pneumonitis, respiratory failure, and unusual radiological presentation rather than the more classical renal failure.

It was reported that diffuse interstitial infiltrates may represent an initial and rare manifestation of the disease. Approximately 40 cases have been reported so far [15].

The second pulmonary presentation was consistent with the typical WG radiological picture.

Thus, our patient had GPA as occurs in a patient with RA, and this association is rare.

Draibe and Salama [9] described six patients with RA who subsequently developed AAV, mostly with MPA. In addition, they performed a literature search using the terms ANCA, vasculitis, and RA and found a total of 29 case reports describing this association between AAV and RA. Of these cases, 13 patients had an overlap between RA and GPA.

This association is perplexing. Lyons *et al.* [18] reported that the genetic basis of the clinical and immunological AAV subsets has recently been described through genome-wide association studies and appear to be different between proteinase-3 and myeloperoxidase AAV, with the most significant associations with *HLA* genes, implicated in other autoimmune diseases.

Possible reasons for the association between systemic AAV and RA may be the common genetic predispositions to autoimmunity that involve the *HLA* region or genes such as *PTPN22*, reported in series of both RA and AAV [19–22]. However, another possibility is the use of tumor necrosis factor (TNF) antagonists, which may have predisposed to the development of secondary autoimmune disease. A French nationwide survey identified 39 cases of vasculitis induced following the use of TNF antagonists [23], whereas a larger series of 379 cases of anti-TNF agent-induced autoimmune diseases identified 118 patients with vasculitis, most of whom only showed cutaneous leukocytoclastic vasculitis, and

11 (9.3%) were positive for ANCA [24]. Draibe and Salama [9] reported that only two patients were treated with anti-TNF- $\alpha$  (infliximab and etanercept) and subsequently developed MPA.

Our patient received adalimumab, a recombinant human IgG1 monoclonal antibody specific for human TNF, as a part of RA management before the appearance of GPA.

## Conclusion

We report a new case of GPA developing during adalimumab therapy for RA. This clinical observation must be considered in all patients treated with anti-TNF. On the basis of the previously published cases of AAV associated with RA, as well as our case, the suggestion of a rare form of an AAV autoimmune overlap should be recognized and investigated for rapid initiation of appropriate management.

## Financial support and sponsorship

Nil.

## Conflicts of interest

There are no conflicts of interest.

## References

- Frankel SK, Cosgrove GP, Fischer A, Meehan RT, Brown KK. Update in the diagnosis and management of pulmonary vasculitis. *Chest* 2006; **129**:452–465.
- Schwarz MI, Brown KK. Small vessel vasculitis of the lung. *Thorax* 2000; **55**:502–510.
- Kalluri R, Meyers K, Mogyorosi A, Madaio MP, Neilson EG. Goodpasture syndrome involving overlap with Wegener's granulomatosis and antiglomerular basement membrane disease. *J Am Soc Nephrol* 1997; **8**:1795–1800.
- Weber MF, Andrassy K, Pullig O, Koderisch J, Netzer K. Antineutrophil cytoplasmic antibodies and antiglomerular basement membrane antibodies in Goodpasture's syndrome and in Wegener's granulomatosis. *J Am Soc Nephrol* 1992; **2**:1227–1234.
- Derrett-Smith EC, Nihtyanova SI, Harvey J, Salama AD, Denton CP. Revisiting ANCA-associated vasculitis in systemic sclerosis: clinical, serological and immunogenetic factors. *Rheumatology (Oxford)* 2013; **52**:1824–1831.
- Tetikurt C, Yuruyen M, Tetikurt S, Bayar N, Ozdemir I. Propylthiouracil induced lupus-like or vasculitis syndrome. *Multidiscip Respir Med* 2012; **7**:14.
- Gaber LW, Wall BM, Cooke CR. Coexistence of anti-neutrophil cytoplasmic antibody-associated glomerulonephritis and membranous glomerulopathy. *Am J Clin Pathol* 1993; **99**:211–215.
- Tse WY, Howie AJ, Adu D, Savage CO, Richards NT, Wheeler DC. Association of vasculitic glomerulonephritis with membranous nephropathy: a report of 10 cases. *J Nephrol Dial Transplant* 1997; **12**: 1017–1027.
- Draibe J, Salama AD. Association of ANCA associated vasculitis and rheumatoid arthritis: a lesser recognized overlap syndrome. *Springer Plus* 2015; **4**:50.
- Aletaha D, Neogi T, Silman AJ, et al. Rheumatoid arthritis classification criteria: an American College of Rheumatology/European League Against Rheumatism collaborative initiative [published correction appears in *Ann Rheum Dis*. 2010; **69**(10): 1892]. *Ann Rheum Dis* 2010; **69**: 1580–1588.
- Sorensen SF, Slot O, Tvede N, Petersen J. A prospective study of vasculitis patients collected in a five years period evaluation of the Chapel Hill nomenclature. *Ann Rheum Dis* 2000; **59**:478–482.
- Jennette JC, Falk RJ, Bacon PA, et al. Revised International Chapel Hill Consensus Conference nomenclature of vasculitides. *Arthritis Rheum* 2012; **65**:1–11.
- Leavitt RY, Fauci AS, Bloch DA, et al. The American College of Rheumatology 1990 criteria for the classification of Wegener's granulomatosis. *Arthritis Rheum* 1990; **33**:1101–1107.
- Koldingsnes W, Nossent H. Epidemiology of Wegener's granulomatosis in Northern Norway. *Arthritis Rheum* 2000; **43**:2481–2487.
- Tattersfield AE, Schwarz MI, Brown KK. Small vessel vasculitis of the lung. *Thorax* 2000; **55**:502–510.
- Belavic Z, Vitas B, Doko A, Baskot A, Polovic A, Mlinac-Lucijanac M. Multiple no dose shadows of the lungs as a differential diagnosis problem. *Acta Med Croatica* 2006; **60**:265–271.
- Jolly M, Molta C, Hoffman G. Wegener's granulomatosis: pitfalls in the management of pulmonary disease: a case of Wegener's granulomatosis with a hilar mass. *J Rheumatol* 2000; **27**:2511–2512.
- Lyons PA, Rayner TF, Trivedi S. Genetically distinct subsets within ANCA-associated vasculitis. *N Eng J Med* 2012; **367**:214–223.
- Farago B, Talian GC, Komlosi K, Nagy G, Berki T, Gyetvai A, et al. Protein tyrosine phosphatase gene C1858T allele confers risk for rheumatoid arthritis in Hungarian subjects. *Rheumatol Int* 2009; **29**:793–796.
- Jagiello P, Aries P, Arming L, Wagenleiter SE, Csernok E, Hellmich B, et al. The PTPN22 620 W allele is a risk factor for Wegener's granulomatosis. *Arthritis Rheum* 2005; **52**:4039–4043.
- Johansson M, Arlestig L, Hallmans G, Rantapaa-Dahlqvist S. PTPN22 polymorphism and anti-cyclic citrullinated peptide antibodies in combination strongly predicts future onset of rheumatoid arthritis and has a specificity of 100% for the disease. *Arthritis Res Ther* 2006; **8**:R19.
- Lee AT, Li W, Liew A, Bombardier C, Weisman M, Massarotti EM, et al. The PTPN22 R620W polymorphism associates with RF positive rheumatoid arthritis in a dose-dependent manner but not with HLA-SE status. *Genes Immun* 2005; **6**:129–133.
- Saint Marcoux B, De Bandt M. Vasculitides induced by TNF alpha antagonists: a study in 39 patients in France. *Joint Bone Spine* 2006; **73**:710–713.
- Ramos-Casals M, Brito-Zeron P, Soto MJ, Cuadrado MJ, Khamashta MA. Autoimmune diseases induced by TNF-targeted therapies. *Best Pract Res Clin Rheumatol* 2008; **22**:847–861.